TAN TOCK SENG HOSPITAL

MEDICAL DIGEST

APRIL - JUNE 2017

MCI (P) 094/08/2016

11 Jalan Tan Tock Seng
Singapore 308433

Tel: 6256 6011
Fax: 6252 7282

www.ttsh.com.sg

Medical Digest is a quarterly publication of Tan Tock Seng Hospital written by healthcare providers for healthcare providers, as a service to the medical community.

FROM THE EDITOR

How should we practise Medicine? Let me paint a picture by telling a few stories from another profession.

In early 2017, the Michelin guide made a mistake when it gave a star in its web site to restaurant Bouche à Oreille in Bourges, when it should have been awarded to one of the same name in Boutervilliers. The error was corrected after a week. The owner of the Bourges restaurant Véronique Jacquet admitted she never hoped to win a Michelin star. "Oh no, not at all," she told *Le Parisien* newspaper. "I cook with my heart."

A shop in Gion, Kyoto, Kinana, apparently makes the best ice-cream in Japan. The owner makes it a point to travel to and select the best 'kuromame' black beans from the Tamba region of Hyogo and Kyoto and 'daizu' soybeans from Hamanaka-cho in Hokkaido. This personal attention to detail is known as こだわり(kodawari). The reviewer in the Kyoto Foodie web site wrote: "Any business in Japan that isn't into kodawari really isn't worth patronizing".

In a New York Times article on 1 March 2010 about the excellent Californian wines, Paul Draper of Ridge Vineyards was reported to say, "Every year we're trying to learn something that will push us 1 percent or 5 percent forwards, and it's gone on for 40 years."

In the introduction to French Country Cooking by the Roux brothers (Bracken Books 1994), they wrote about their appreciation of regional cooking produced by the locals, which is good, honest and not flashy: "The sight and smell of the dishes we are served cause the conversation to stop … with fine seasonal vegetables resting on top, simply peeled and never, ever fancily 'turned'".

Simplicity, passion, honesty, pursuit of perfection, humility; these are universal human traits that the doctor will do well to acquire.

Dr Leong Khai Pang
EDITOR
Medical Digest

MEDICAL DIGEST

EDITOR
Leong Khai Pang

ASSOCIATE EDITORS:
Charmaine Manauis
Raymond Ng
Melissa Tien
Mohd Fadil Muhammad Farhan

MEMBERS:
Tang Yee Lin
Rafael Saclolo
Ivan Huang Kuang Hsin
Noorhazlina bte Ali
Deshan Kumar
Tan Choon Chieh
Shirley Bang
Chong Yaw Khian
Kalaiyarasi Kaliyaperumal
Adeline Teh
Yew Min Sen
Shirlene Ho Shu Min
Gavin Lim Hock Tai
Binedell Trevor Brian

EDITORIAL ASSISTANT
Angie Theonis

COPY EDITOR
Safiyya Mohamed Ali

DESIGNER
Clinton Low

We value your feedback. Please email your questions, comments or suggestions to:
ttsh_ccs@ttsh.com.sg
Please also contact us for notification of change of postal address or requests of additional copies.

While every endeavour is made to ensure that information herein is accurate at the time of publication, Tan Tock Seng Hospital shall not be held liable for any inaccuracies. The opinions expressed in this publication do not necessrily reflect those of Tan Tock Seng Hospital. The contents of this publication may not be reproduced without written permission from the publisher.

TTSH RESEARCH NEWS

Every year, TTSH clinicians publish about 300 scientific papers. In this section, we selected a few reports and asked one of the authors of each to summarise and discuss the clinical relevance of their research. Our theme in this issue are medical disciplines.

RESEARCH EXCERPT 1

Burnout, Psychological Morbidity and Use of Coping Mechanisms among Palliative Care Practitioners: A multi-centre cross-sectional study

Koh MY, Chong PH, Neo PS, Ong YJ, Yong WC, Ong WY, Shen ML, Hum AY. Palliat Med 2015; 29(7):633-42.

Burnout is defined as a state of mental and/or physical exhaustion caused by prolonged exposure to excessive and prolonged stress. Psychological morbidity measures the likelihood of developing anxiety and depression. Palliative care practitioners by virtue of their work are prone to burnout and psychological morbidity.

We conducted a multi-centre study of palliative care units in acute hospitals, inpatient hospices and home hospice care centres in Singapore. We surveyed 273 respondents in total. There were more females (83.4%) than males (16.6%) with the majority of those surveyed being palliative care nurses (58.3%), followed by doctors (28.1%) and social workers (13.6%).

We found that 33% of all those practicing palliative care in Singapore suffer from burnout and 28% from psychological morbidity. Those who worked >60 hours per week were 8.5 times more at risk of emotional exhaustion and 9 times more at risk for burnout compared to those working 40 hours per week. Those who described themselves as more spiritual had less psychological morbidity, less de-personalisation and a greater sense of personal accomplishment. We also found that those working in multiple settings within the same month and those working in home hospice care were at higher risk for burnout and psychological morbidity.

Those who were less burned out used multiple coping mechanisms especially ensuring physical well-being, maintaining clinical variety, setting boundaries, practicing transcendental meditation and quiet reflection, having passion for one's work, having realistic expectations, remembering patients and taking part in organisational activities.

This summary was prepared by Dr Mervin Koh, a senior consultant in the Department of Palliative Medicine, Tan Tock Seng Hospital.

IMPORTANCE IN CLINICAL PRACTICE

Palliative care doctors, nurses and social workers are exposed to the daily trauma of death and dying as part of their work. Our study suggests that around one-third of all palliative care practitioners in Singapore suffer from burnout and psychological morbidity.

Palliative care administrators should look into reducing the number of working hours per week for palliative care practitioners, and think of measures to reduce burnout especially in home hospice care practitioners. In addition, both palliative care practitioners and administrators should themselves be actively involved in activities to reduce the risk of burnout, as well as create conducive environments to implement and encourage such pursuits. These may include group exercise sessions, meditation sessions and talks to increase awareness about care burnout and coping mechanisms.

RESEARCH EXCERPT 2



Outcomes of a multimodal cognitive and physical rehabilitation programme for persons with mild dementia and their caregivers: a goal-oriented approach

Chew J, Chong MS, Fong YL, Tay L. Clin Interv Aging 2015; 10:1687-94.

As the number of persons living with dementia increases, there is a need to develop effective interventions for Alzheimer's disease. A growing body of literature suggests that exercise has a positive effect on cognition. Cognitive rehabilitation is another modality of treatment that focuses on strategies to maintain or cope with memory impairment, with the aim of decreasing functional disability and maximising social participation and engagement in activities of daily living. The MINDVital programme at Tan Tock Seng Hospital is a multidisciplinary rehabilitation programme for persons with mild dementia, comprising once-weekly small group therapy sessions, with each session lasting 3 hours over 8 consecutive weeks. Each weekly session includes the following activities: 1) 45-minute multicomponent physical exercise programme of light aerobic exercises, range of motion and resistance exercises, as well as balance training; 2) One-hour cognitive stimulation and rehabilitation with social and mental activities such as reminiscence therapy; and 3) 30-minute tailored individualised activities delivering person-centred care.

This summary was prepared by Dr Justin Chew, a registrar in the Department of Geriatric Medicine, Tan Tock Seng Hospital.

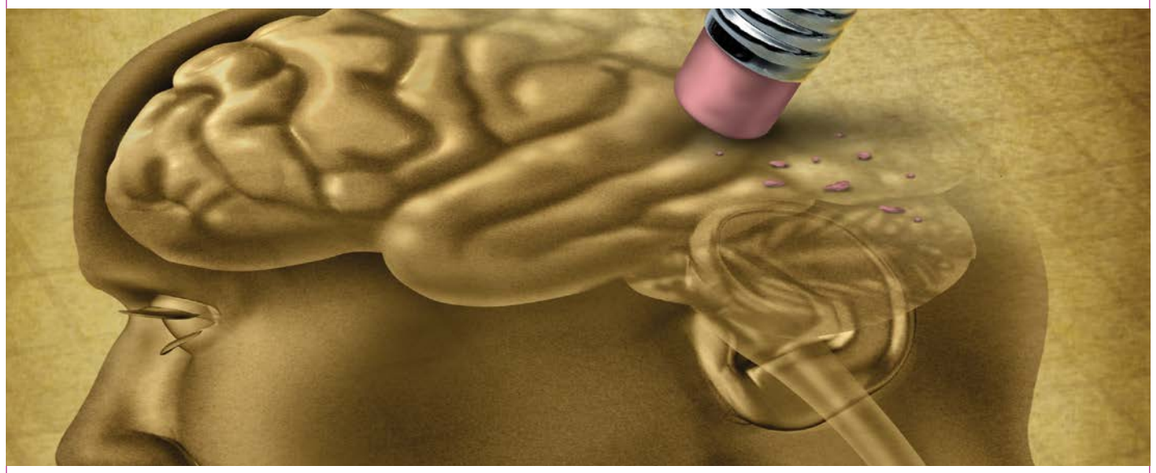

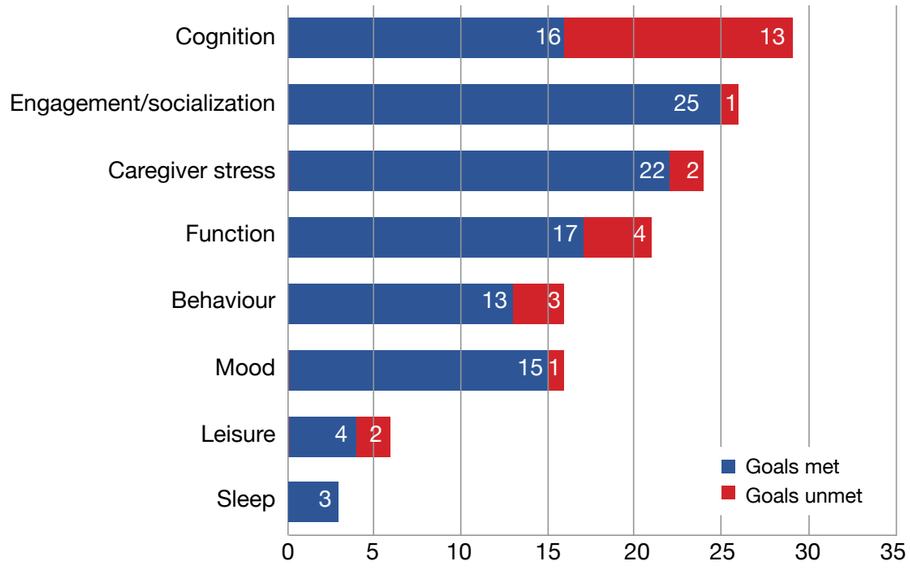

Figure 1. Types and number of goals met or unmet. (Figure obtained from Chew et al. 2015)

IMPORTANCE IN CLINICAL PRACTICE

Our study shows that non-pharmacological interventions incorporating physical exercise, cognitive rehabilitation and stimulation have potential benefit in persons with dementia and their caregivers. Given the clinical heterogeneity of the Alzheimer's disease syndrome where deficits may be subtle and not reflected on standard scales, a goal-oriented approach enabled an individualised approach to measuring outcomes and may have better reflected clinically relevant change important to the individual and caregiver. In addition, further insights were gleaned from the goal-setting process. Contrary to the conventional importance placed on cognitive function, cognitive goals only comprised one-fifth of goals set, while a significant proportion identified goals to reduce caregiver burden. Family caregivers are vulnerable to the psychological, physical, financial, and social strains that are associated with caregiving. Interventions that involve the caregiver may contribute to the reduction in caregiver burden through shared decision-making and goal setting.

In our study, we examined the effect of MINDVital for persons with mild dementia and their caregivers using conventional measures of cognition, behaviour, quality of life, and caregiver burden together with goal attainment scaling, an individualised quantitative outcome measure. Individual goals were set by the participant and the caregiver at the start of the programme. Goals identified included improving cognitive targets, improving engagement and socialisation, reducing caregiver stress, and improving physical function, behaviour, mood, and sleep. At the end of the programme, while median scores in the cognitive, functional, and quality of life measures did not differ significantly pre- and post-intervention, a majority of participants were assessed to have met their individual goals as measured by goal attainment scaling (figure 1). The intervention also had a positive impact on caregiver burden.

TTSH Research News is curated and edited by ***DR MELISSA TIEN****, a consultant in the Department of Opthalmology, Tan Tock Seng Hospital.*

FEATURE ARTICLE

WORKING WITH ME, ROBOT-AIDED REHABILITATION: CHANGING PARADIGMS, CHANGING LANDSCAPES

Introducing the TTSH Centre of Advanced Rehabilitation Therapeutics (TTSH-CART)

TTSH-CART, nestled in a quiet corner on level 5 TTSH Medical Centre, opened its doors on 18 August 2011. Conceptualised as an ambulatory rehabilitation specialist clinic and outpatient rehabilitation centre spearheading the deployment and clinical integration of advanced rehabilitation technology, CART delivers robot-aided therapy (RAT), virtual reality-based therapy and conventional rehabilitation therapies within holistic combinatory rehabilitation protocols. Movement retraining, intensive practice and activities of daily living (ADL) training are integrated with innovative RAT and virtual reality technologies to achieve goal-orientated and optimal outcomes for patients. The main purpose of this integration is to increase patients' engagement, participation and activity in a fun and interactive way.

CART's mission is to provide comprehensive, multidisciplinary goal-directed rehabilitation therapies integrated with innovative robotic and virtual reality technologies to optimise outcome after stroke, brain and spinal cord injuries.

Figure 1. The TTSH-CART Team.

CART's multidisciplinary team consists of 15 rehabilitation professionals including nurses, physiotherapists, occupational therapists, speech therapists and psychologists (figure 1). Daily sessional specialist rehabilitation clinics have been in operation since its opening.

Rehabilitation, robots and the brain

Advances in neuroscience and rehabilitation practice heralded the advent of robots for rehabilitation, in particular for neurological disorders. The rise of rehabilitation robotics parallels the rapid advances in technology, computers and engineering.[1] From a technical perspective, the rapid growth in this field can be attributed to a confluence of factors – the emergence of hardware for haptics and advanced robotics that provide a safe training environment for the patient and the therapist; and, a drop in computing costs and the emergence of software for real-time control. Clinical drivers include the aging population and worldwide shortage of rehabilitation professionals. The entry of a neurorobot in the therapeutic field has been a game-changer which realises the multidimensional benefits of RAT through therapeutic alliances and leverages on the strengths of robots – automation, adaptability, automated training progression, continuous monitoring, virtual reality feedback, and kinematic measurements and reporting (figure 2).[2]

Thus, RAT takes advantage of vital elements to enhance experience-dependent plasticity[3] such as active engagement in intensive therapy, and task-specific and highly-repetitive training[4], which are key components to movement recovery. RAT also reduces the workload and physical effort of the therapist and more dependent patients, allowing more intensive and repetitive motions, and longer duration of therapy. It provides a quantitative measure of motor recovery by providing real-time and processed kinematic (spatial, speed, movement trajectories, latencies) and kinetic (force, assistance) data. The scarce availability of skilled labour to perform these repetitions fuels the developmental diversity and penetration of therapeutic robots in the rehabilitation milieu.[5]

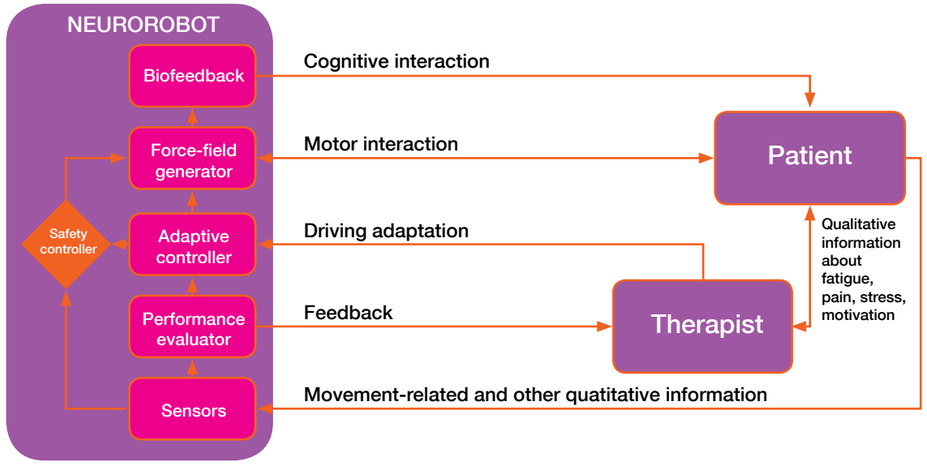

Figure 2. Multi-dimentional interactions operant in robot-aided therapy.

Rehabilitation robotics (Upper and lower limb robotics)

UPPER LIMB ROBOTICS

Observational studies have shown that patients are not engaged optimally when performing movement repetitions during conventional upper limb rehabilitation sessions. Patients carry out as few as 32 repetitions while a robotic-assisted therapy session can deliver about 1000 repetitions.[6-8] Such high repetitions of movement practice have been shown to facilitate neuroplasticity and promote brain recovery. A Swiss group studied chronic stroke patients with moderate to severe arm paresis who trained for 45 minutes thrice weekly, for a total of 8 weeks, on an exoskeleton robot allowing task-specific training in three dimensions.[9] The RAT group had a significantly higher rate of recovery of arm motor function compared to the group receiving conventional therapy after 8 weeks of training, although the extent of recovery remained similar at 34 weeks. The therapist became more efficient because not only do patients achieve higher exercise and training intensity, several can undergo RAT simultaneously, with minimal supervision.

There are few cost effectiveness studies of RAT used for chronic stroke upper limb impairment, but one suggests that RAT costs the same as similar durations of intensive human-based therapies[10], and small but significant and enduring gains in arm motor function persist for about 9 months after cessation of RAT, longer than with standard therapy.[8]

We briefly describe two commercially available upper limb robotic systems.

1. **InMotion Robots**
   InMotion ARM is a planar robot targeting shoulder-elbow movements (figure 3). It can be combined with the InMotion HAND for assisted grasp training. Separately, the InMotion WRIST works on wrist and forearm rotation movements. The InMotion robot provides an assistance-as-needed mode of unilateral arm training. It enables

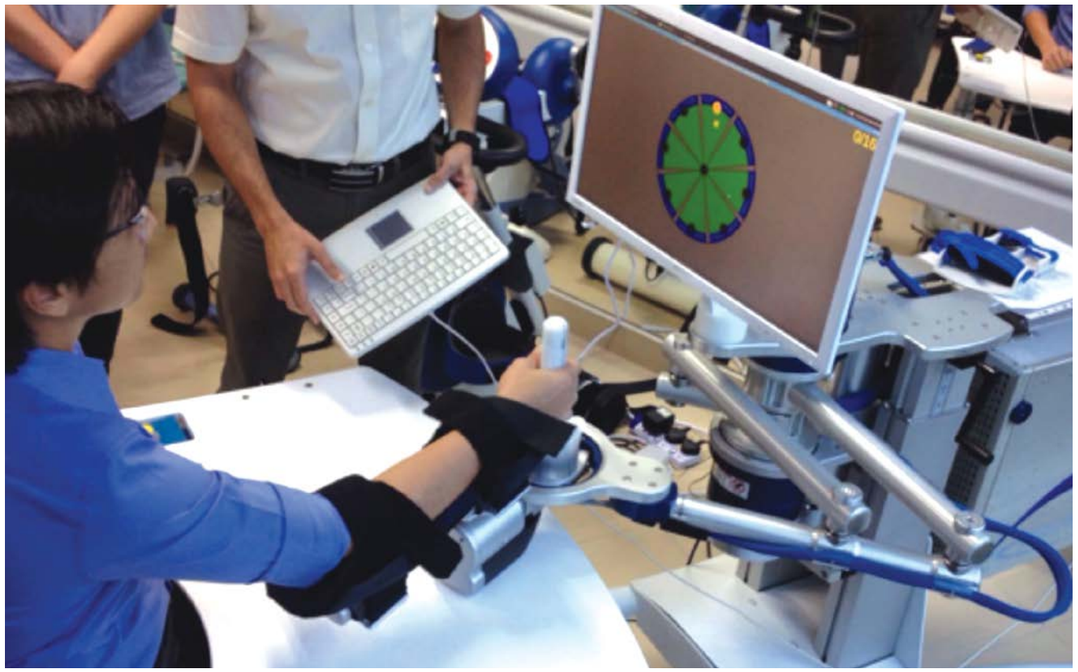

Figure 3. InMotion ARM Robot, with the insert showing a record of the movements.

up to 1024 repetitive movements in a single training session and users are able to monitor their performance via quantitative and visual feedback. An evaluation programme also allows for robotic measurement of upper limb recovery outcomes.

2. **Armeo Robots**
The Armeo Therapy Concept consists of three training systems integrated into a common software featuring interactive games for progressive training with diminishing mechanical support: the Armeo Power (figure 4) with multi-dimensional degrees of freedom, caters for users with very weak arms with movement assistance from the motor actuated exoskeleton; the Armeo Spring uses an arm unweighting orthosis consisting of a spring-embedded user-powered exoskeleton that can be used for those with some active movements or moderate level of weakness (figure 5); and the Armeo Boom supports users' arms via a sling-based set-up to focus on the training of motor coordination (figure 6).

Figure 4. Armeo Power. (Source: http://www.hocoma.com)

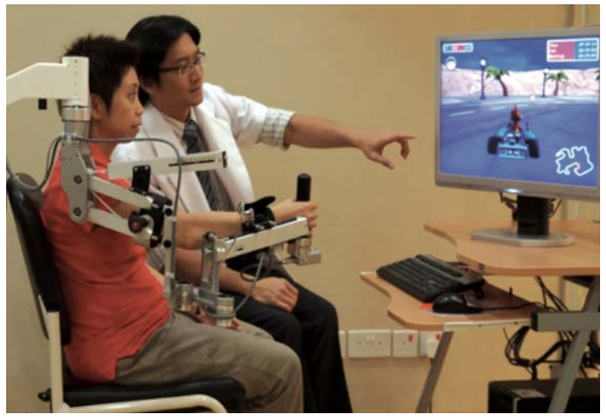

Figure 5. Armeo Spring.

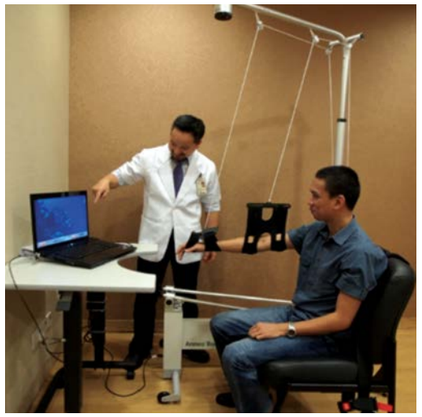

Figure 6. Armeo Boom.

LOWER LIMB ROBOTICS
Traditionally, the technique of partial bodyweight treadmill training (PBWSTT) is used for intensive gait rehabilitation. The PBWSTT improves the strength of the lower extremities and the locomotion pattern by having the patient walk on a treadmill with an overhead safety harness. The bodyweight support can be adjusted to suit the ability of the individual's lower extremity to bear weight. Therapists have to effect the appropriate weight shift and placement of the legs during the stance and swing phases of gait cycle. This laborious technique requiring three therapists to facilitate the supported standing, stepping and repetitive gait cycle is believed to activate the central pattern generators located in the patient's medulla or cervical cord.

As manual PBWSTT techniques are inefficient and effortful, they have largely been replaced by various robotic gait trainer systems which deliver the same training by means of a powered exoskeleton coupled with the treadmill system. High-intensity stepping exercise up to ~1000 gait cycles per session can be achieved compared to 50–100 steps per session for dependent patients. Examples of such systems include Lokomat (Hocoma AG, Switzerland), LokoHelp (Lokohelp Group, Germany), and ReoAmbulator (Motorika USA Inc.).

The TTSH Rehabilitation Centre is the first hospital-based rehabilitation facility in Singapore to introduce the Lokomat system for clinical use in August 2008 (figure 7). The Lokomat is the world's first robotic gait orthosis that automates locomotion therapy on a treadmill and has been extensively evaluated in the clinic. One of its major advantages is that it uses very little manpower. A key feature of the Lokomat is the Augmented Feedback which enables the individual to engage in fun, motivating and interactive virtual reality games during the session.

The use of augmented feedback may be beneficial for better engagement and outcome.[11-12] Wagner et al.[13] demonstrated that premotor and parietal areas show increased activity during walking with a virtual reality training paradigm, compared to walking with mirror- and movement-unrelated feedback. Previous research has shown a relationship between the premotor-parietal network and motor planning and intention. Hence, movement-related interactive feedback enhances motor planning and motor intention, and may promote gait recovery during rehabilitation.

Figure 7. Lokomat training session and augmented reality feedback.

There is evidence that robot-aided gait therapy (RAGT) is beneficial and has higher efficacy than overground walking therapy for more dependent stroke patients without otherwise serious adverse events or major safety issues.[14] Using a variety of automated robotic gait systems (as above), patients who were non-ambulant were 2.34 times more likely to be able to walk independently after RAGT compared to overground walking. This positive benefit was 3.43 times more likely if RAGT was started within 3 months of the stroke. However, RAGT was not significantly superior to overground walking for improving walking speed or walking capacity. Hence, RAT in combination with usual physiotherapy is relevant for enhancing functional mobility.[14] The addition of follow-on conventional therapy translates the gains in motor control, limb use, strength and mobility to tasks such as overground walking, stair climbing and ADLs which impact functional independence and quality of life. Patients with incomplete traumatic spinal cord injury using Lokomat may also derive benefits related to more intensive gait cycles and expend less effort in locomotor training.[15] RAGT has been applied to various other diagnostic groups such as traumatic brain injuries, Parkinson's disease, and cerebral palsy, with initial promising results and no serious adverse events.

Gaming in rehabilitation

Virtual reality and interactive video gaming devices such as Nintendo Wii and Microsoft Xbox Kinect 360 systems are easily accepted, incorporated and deployed in conventional therapy. The advantage of video gaming over traditional stroke upper limb therapy is the significant increase in the amount of arm movement elicited, low cost, ease of use and acceptability. Initial clinical trials have shown promising results in terms of gain in overall function and ADLs after Wii gaming with a low dropout rate.[18-19] Devices such as Handtutor or 3DTutor use simple sensor glove technology in virtual reality games. ReJOYCE, a hand, arm and shoulder rehabilitation workstation, used unilaterally or bilaterally, is enriched with fun and interactive games and promotes motor recovery and improves shoulder mobility and hand dexterity. These devices have been used in individual and group therapies within a goal-directed circuit training programme developed in TTSH-CART since 2015. These programmes help patients to develop self-efficacy in goal setting, independence with the use of technology, and the group dynamics and social interaction help to motivate patients to exercise independently.

CART: 5 years on and beyond

CART offers a one-stop experience for new patients by combining their specialist rehabilitation consultation with the therapists' assessment on the same day. In addition, assessment and training are enhanced through a variety of robotic devices targeting locomotor function, proximal and distal arm recovery and function, virtual reality gaming platforms for motor, balance, visual, cognitive retraining and circuit training.

Since 2014, CART collaborated with advanced Paediatric Medicine Specialists from National University Hospital to provide robotic aided rehabilitation programmes (Lokomat and Armeo Spring) to children aged above 10 years and adolescents with cerebral palsy, brain injuries and spinal cord injuries. Prior medical screening is provided by a specialist rehabilitation physician at TTSH-CART. This illustrates the versatility of RAT across ages and diseases, with technology supporting older children who are growing up with chronic developmental conditions. A detailed description of our clinical programmes is available here: https://knowledge.hocoma.com/clinical-practice/armeo/clinical-integration/ao-cex-8.html

Patients receiving RAT are monitored at four specified time points during their treatment journey (at baseline, post-RAT, post-conventional therapy and after 1 month) through two rehabilitation functional databases, adult and paediatric, both administered by TTSH-CART's therapists. These valuable data are used to refine RAT protocols in terms of clinical selection criteria, programme intensity and duration.[16-17] Since 2012, CART has been an active participating site in the international network of ARTIC (Advanced Robotic Therapy Integrated Centres), in collaboration with 13 other centres worldwide.

Looking to the future for rehabilitation technology

CART is a leading clinical partner within an ecosystem of rehabilitation research, collaborating with leading scientists in academic institutions and industry partners, aiming to test-bed and validate novel devices for feasibility, efficacy, productivity and commercial potential. In the past 5 years, human trials @TTSH-CART have tested Brain-Computer Interface systems for wrist and hand rehabilitation, swallowing therapy for neurogenic dysphagia, portable low-cost end effector arm robots, intelligent sensing treadmills and virtual reality rehabilitation systems. These are targeted towards local innovation to improve portability, design and deployment and steer such technologies to successful deployment in the intermediate long-term care sector and for home use.[20-24]

The next lap for development of rehabilitation technologies and robots focuses on the compelling need to address the burden of care in the chronic rehabilitation continuum. These include portable, less complex, compact robots which are easily managed by therapy aides in the community, lower cost robots which are cost-effective, tele-rehabilitation, and devices which help to maintain or track function at home with gamification.

In the pipeline for research @TTSH-CART are exploratory trials into post-stroke sensory and proprioceptive quantification using robotics, soft powered exoskeletal suits for arm and hand retraining, technology-assisted upper extremities movement measurement system for tele-rehabilitation, mobile robotic assistive balance trainers, device-free passive tracking systems for fall detection during home based rehabilitation and customised virtual reality rehabilitation systems to monitor and motivate older adults to reduce frailty.

REFERENCES

1. *Krebs HI. Robotic technology and physical medicine and rehabilitation. Eur J Phys Rehabil Med 2012; 48:319-24.*
2. *Iosa M, Morone G, Cherubini A, Paolucci S. The three laws of neurorobotics: A review on what neurorehabilitation robots should do for patients and clinicians. J Med Bio Eng 2016; 36:1-11.*
3. *Saposnik G, Levin M. Virtual reality in stroke rehabilitation: a meta-analysis and implications for clinicians. Stroke 2010; 42:1380-6.*
4. *Langhorne P, Coupar F, Pollock A. Motor recovery after stroke: a systematic review. The Lancet Neurology 2009; 8(8):741-74.*
5. *Marchal-Crespo L, Reinkensmeyer DJ. Review of control strategies for robotic movement training after neurologic injury. J Neuroeng Rehabil 2009; 6:20.*
6. *Lang CE, MacDonald JR, Reisman DS, Boyd L, Jacobson Kimberley T, Schindler-Ivens SM, et al. Observation of amounts of movement practice provided during stroke rehabilitation. Arch Phys Med Rehabil 2009; 90:1692-8.*
7. *Volpe BT, Krebs HI, Hogan N, Edelstein L, Diels C, Aisen M. A novel approach to stroke rehabilitation: robot-aided sensorimotor stimulation. Neurology 2000; 54, 1938-44.*
8. *Lo AC, Guarino PD, Richards LG, Haselkorn JK, Wittenberg GF, Federman DG, et al. Robot-assisted therapy for long-term upper limb impairment after stroke. N Eng J Med 2010, 362:1772-83.*
9. *Klamroth-Marganska V, Blanco J, Campen K, Curt A, Dietz V, Ettlin T, et al. Three-dimensional, task-specific robot therapy of the arm after stroke: a multicentre, parallel-group randomised trial. Lancet Neurol 2014; 13(2):159-66.*
10. *Wagner TH, Lo AC, Peduzzi P, Bravata DM, Huang GD, Krebs HI, et al. An economic analysis of robot-assisted therapy for long-term upper-limb impairment after stroke. Stroke 2011; 42(9):2630-2.*
11. *Brütsch K, Koenig A, Zimmerli L, Merillat-Koeneke S, Riener R, Jäncke L, et al. Virtual reality for enhancement of robot-assisted gait training in children with neurological gait disorders. J Rehabil Med 2011; 43:493-9.*
12. *Zimmerli L, Jacky M, Lünenburger L, Riener R, Bolliger M. Increasing patient engagement during virtual reality based motor rehabilitation. Arch Phys Med Rehabil 2013; 94:1737-46.*
13. *Wagner J, Solis-Escalante T, Scherer R, Neuper C, Müller-Putz G. It's how you get there: walking down a virtual alley activates premotor and parietal areas. Front Hum Neurosci 2014; 8:93.*
14. *Mehrholz J, Elsner B, Werner C, Kugler J, Pohl M. Electromechanical-assisted training for walking after stroke. Cochrane Database Syst Rev 2013; 7:CD006185.*
15. *Shin JC, Kim JY, Park HK, Kim NY. Effect of robotic-assisted gait training in patients with incomplete spinal cord injury. Ann Rehabil Med 2014; 38(6):719-25.*
16. *WKC Kuah, CY Ng, VA Deshmukh, SGK Chua, HLL Hon. Stroke upper limb outcomes after robotics-assisted therapy at a rehabilitation center in Singapore. Proceedings of the 6th Singapore Health and Biomedical Congress 2015. Annals Acad Med 2015; 44(S10):PP-AH-16.*
17. *VA Deshmukh, CWK Kuah, CY Ng, HLL Yam, YH Ooi, KSG Chua. The efficacy of a gravity-assisted upper limb device on stroke patients with moderate to severe arm paresis in an outpatient rehabilitation setting: A comparison between two clinical programs. Proceedings of the 7th Singapore Health and Biomedical Congress 2016. Annals Acad Med 2016; 45(S9):AH-68.*
18. *Loh YJ, Soon Yin T, Xu D, Thia E, Pei Fen C, Kuah CW, et al. A feasibility study using interactive commercial off-the-shelf computer gaming in upper limb rehabilitation in patients after stroke. J Rehabil Med 2010; 42(5):437-41.*
19. *Kong KH, Loh YJ, Thia E, Chai A, Ng CY, Soh YM, et al. Efficacy of a virtual reality commercial gaming device in upper limb recovery after stroke: A randomized, controlled study. Top Stroke Rehabil 2016; 23(5):333-40.*
20. *Yang H, Guan C, Chua KS, Chok SS, Wang CC, Soon PK, et al. Detection of motor imagery of swallow EEG signals based on the dual-tree complex wavelet transform and adaptive model selection. J Neural Eng 2014; 11(3):035016.*
21. *Ang KK, Guan C, Phua KS, Wang C, Zhou L, Tang KY, et al. Brain-computer interface-based robotic end effector system for wrist and hand rehabilitation: results of a three-armed randomized controlled trial for chronic stroke. Front Neuroeng 2014; 7:30.*
22. *Chua KS, Chee J, Wong CJ, Lim PH, Lim WS, Hoo CM, et al. A pilot clinical trial on a Variable Automated Speed and Sensing Treadmill (VASST) for hemiparetic gait rehabilitation in stroke patients. Front Neurosci 2015; 9:231.*
23. *Ang KK, Chua KS, Phua KS, Wang C, Chin ZY, Kuah CW, et al. A randomized controlled trial of EEG-based motor imagery brain-computer interface robotic rehabilitation for stroke. Clin EEG Neurosci. 2015; 46(4):310-20.*
24. *Hussain A, Budhota A, Hughes CM, Dailey WD, Vishwanath DA, Kuah CW, et al. Self-paced reaching after stroke: a quantitative assessment of longitudinal and directional sensitivity using the H-man planar robot for upper limb neurorehabilitation. Front Neurosci 2016; 10:477. eCollection 2016.*

Left to right: Dr Loh Yong Joo is a consultant, Dr Karen Chua is a senior consultant, Mr Christopher Kuah Wee Keong is a principal occupational therapist, and Dr Wee Seng Kwee is a principal physiotherapist, from the Department of Rehabilitation Medicine, Tan Tock Seng Hospital.

To find us or make a referral, please contact us at:
Tel: (65) 6889 4580 / 4586
Email: CART@ttsh.com.sg
Fax: 6889 4578
Website: www.ttsh.com.sg/cart

CASES WE SAW IN THE WARD, PART 8

We returned to our clinics and found another group of patients with interesting and educational signs. We hope that you will enjoy spotting the signs and making the diagnoses as much as we did.

CASE 1

This 40-year-old lady has a rash on her back for many years (figure 1). The lesions tend to itch and swell when she scratches them. She has no constitutional complaints. What is your diagnosis?

Figure 1. A brown papular rash that has been present for years.

CASE 2

A chest X-ray was ordered for this 70-year-old man because of the complaint of breathlessness (figure 2). The clinical examination was normal. What sign do you see?

Figure 2. A chest X-ray of an elderly man with breathlessness.

CASE 3

This 40-year-old lady with a 15-year history of systemic lupus erythematosus complains bitterly of left sided subcostal pain. The chest X-ray (figure 3) was reported to show right-sided 9th rib fracture, on the opposite side. What do you think has happened on the left?

Figure 3. Chest X-ray of a lady with left-sided subcostal pain. The arrow indicates the site of the fracture in the 9th rib.

CASE 4

Figure 4 shows the trend of the mean cell volume (MCV) of a man who was diagnosed to have HIV infection at the inflexion point in the line. How does HIV raise the MCV?

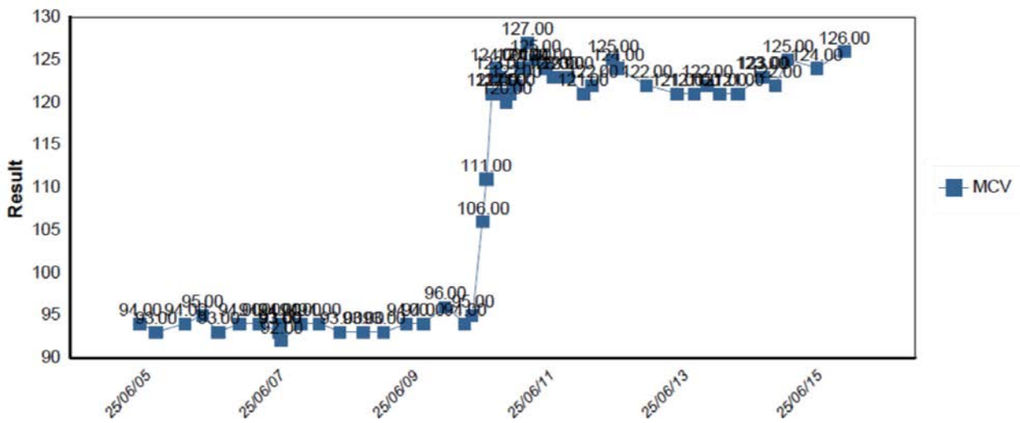

Figure 4. Chart of the mean cell volume (vertical axis) plotted against time (horizontal axis) in an HIV-positive man.

CASE 5

A middle-aged man, treated with sulphasalazine and low-dose prednisolone for rheumatoid arthritis, complains of cough of a week's duration. He is also a chronic smoker. This chest X-ray (figure 5) was ordered to elucidate the reason for the cough. What do you see in the film?

Figure 5. Chest X-ray of a smoker with rheumatoid arthritis complaining of cough for a week.

CASE 6

This elderly lady complained of right hip pain for two weeks. There was no history of trauma. What do you find in her hip X-ray (figure 6)?

Figure 6. Hip X-ray of an elderly lady with atraumatic pain.

CASE 7

This 50-year-old man is suffering from rheumatoid arthritis. He has been a heavy alcohol drinker for many years. He complains of right hip pain, for which this film was requested (figure 7). What is your diagnosis?

Figure 7. Pelvis X-ray of a middle-aged man complaining of right hip pain.

CASE 8

This elderly lady fell and landed on the right elbow. She complained of pain over the olecranon. An X-ray of the joint was taken (figure 8). What sign do you see, and what should you look out for when it is present?

Figure 8. Lateral elbow X-ray of a lady who sustained a fall.

CASE 9

This 40-year old lady was treated for pneumonia 1 year ago. Now she presents with left ankle joint swelling for 9 months. A chest X-ray was taken. Could you provide a single diagnosis to explain both?

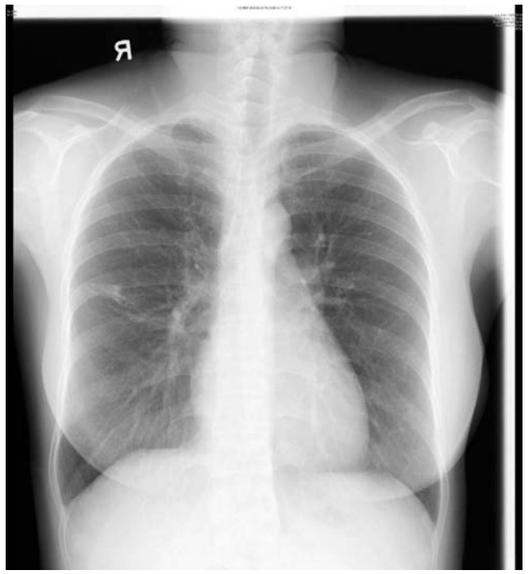

Figure 9. Chest film of a 40-year old lady with left ankle pain.

CASE 10

This 65-year-old lady suffered from recurrent strokes. In an investigation for anaemia, CT abdomen was ordered (figure 10). What findings do you see and do they explain the strokes? Why is she similar to Alan Rickman?

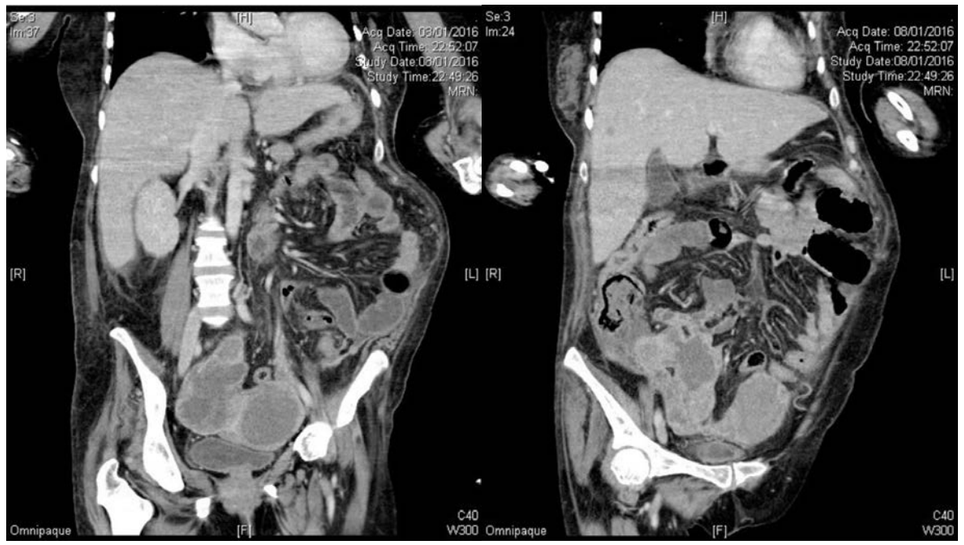

Figure 10. Two coronal sections of the CT scan of the abdomen of a 60-year-old lady.

CASE 11

This 70-year-old lady is asymptomatic so her doctors were surprised to see this ECG (figure 11). What is your diagnosis?

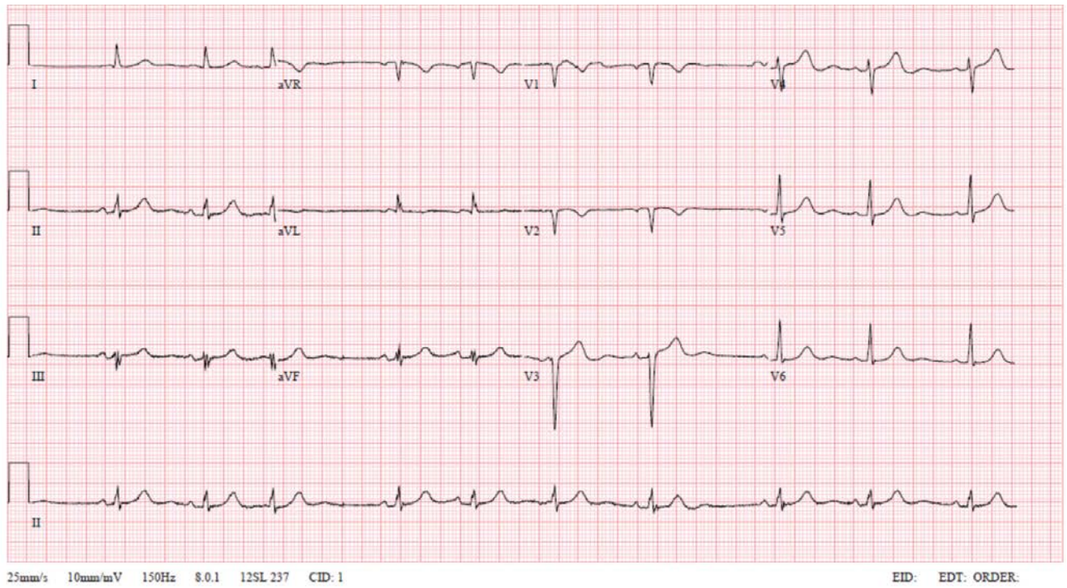

Figure 11. ECG of a fairly healthy 70-year-old lady.

ANSWERS

CASE 1

A brown papular rash that is aggravated by scratching is suggestive of urticaria pigmentosa, a form of mastocytosis. The release of histamine on physical contact, leading to itch and swelling, is known as Darier's sign, described by the father of French Dermatology Ferdinand-Jean Darier. When this phenomenon occurs on the buttocks, it is known as the derriere sign.

CASE 2

There is an indentation of the trachea on the right, at the level of the first rib. The patient developed a large benign cyst in the right hemithyroid.

CASE 3

The patient actually has bilateral 9th rib fractures. They are better seen in these magnified images (figure 12). She was found to have osteoporosis and started receiving treatment for it.

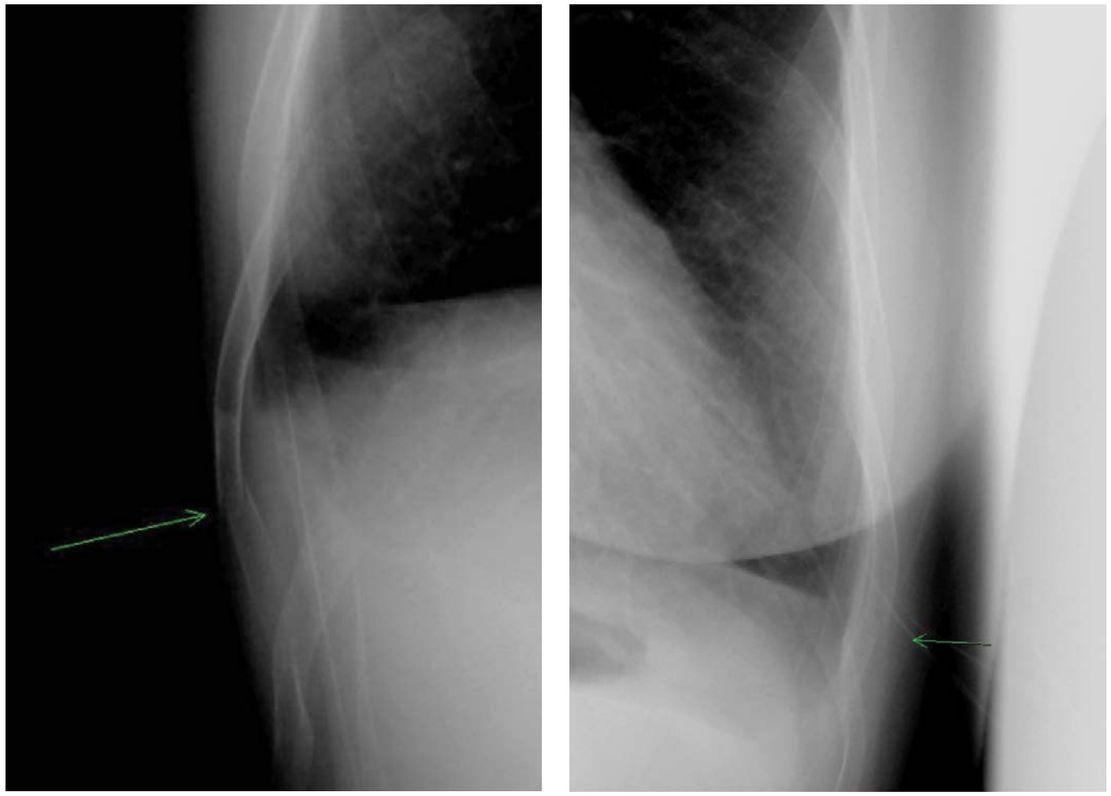

Figure 12. Magnified views of the X-ray of lower right and left chest wall showing the bilateral rib fractures.

CASE 4

HIV itself does not affect the MCV. On the other hand, antiretroviral drugs such as zidovudine and stavudine increase the MCV.[1,2] This change is so reliable that doctors can use this laboratory sign to check for adherence to therapy.

CASE 5

There are 'soft shadows' in the upper zone and nodules in the right lower zone. The patient was suspected to be suffering from pulmonary tuberculosis. The sputum culture returned the atypical *Mycobacterium fortuitum*.

CASE 6

There is a fracture in the right superior pelvic ramus. The image below shows the fracture line indicated by the two arrows (figure 13).

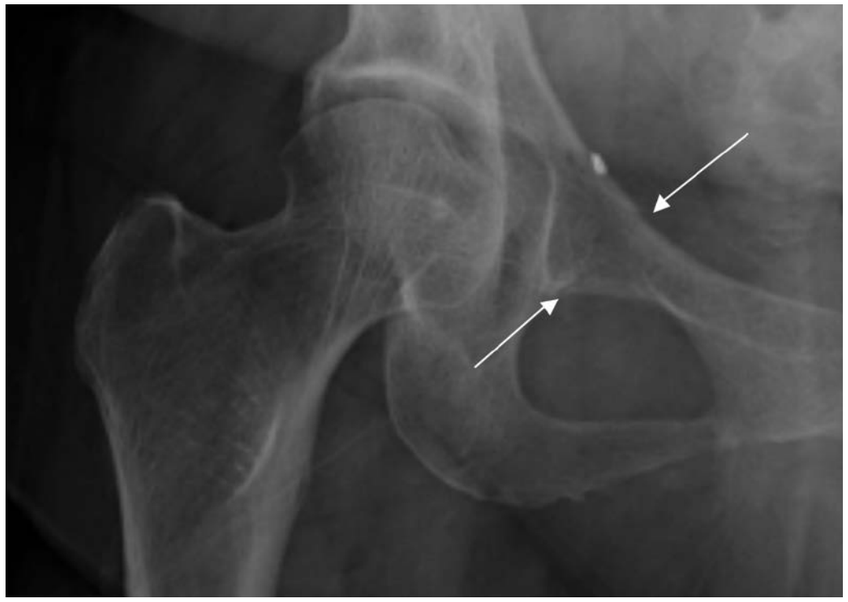

Figure 13. X-ray of the right hip showing a fracture through the superior pubic ramus.

CASE 7

There is a crescent-shaped sclerotic shadow in the right femoral head. As the MRI confirms (figure 14), the patient has developed an avascular necrosis.

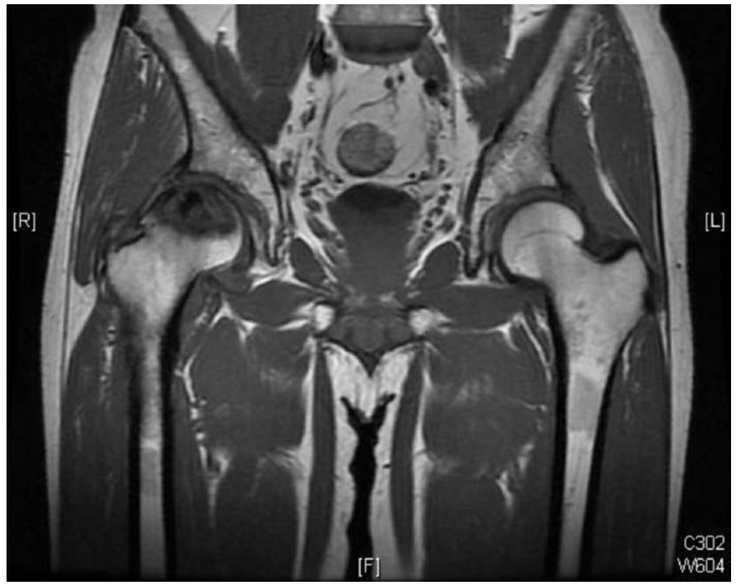

Figure 14. MRI of the pelvis of a 50-year-old man showing avascular necrosis of the right femoral head.

CASE 8

The olecranon is normal. The fat pad sign is present (arrows), suggestive of effusion of the elbow joint (figure 15). The fluid displaces the fat pad outwards, making it visible on X-ray. This sign was first noticed in 1954 and fracture of the radial head has since been associated with it.[3] Fortunately, CT scan of this patient's arm did not reveal any fracture. Perhaps the concern about the fat pad sign is unwarranted as a recent study suggests that this sign occurs very frequently in patients with elbow trauma and often is not associated with anything sinister.[4]

Figure 15. The arrows indicate the anterior border of the lifted fat pad.

Either or both the anterior and posterior fat pads may be lifted. The following X-ray shows mild lifting of the posterior one (figure 16).

Figure 16. Lateral X-ray of the right elbow of a lady with rheumatoid arthritis showing a subtle posterior fat pad sign.

CASE 9

The chest film shows a shadow in the right mid-zone interpreted as scarring, consistent with the history of lung infection. The CT thorax confirms the scarring but tree-in-bud shadows are also found distal to the scar (figure 17). This raises a question of tuberculosis and indeed the organism is found both in the lungs and the joint.

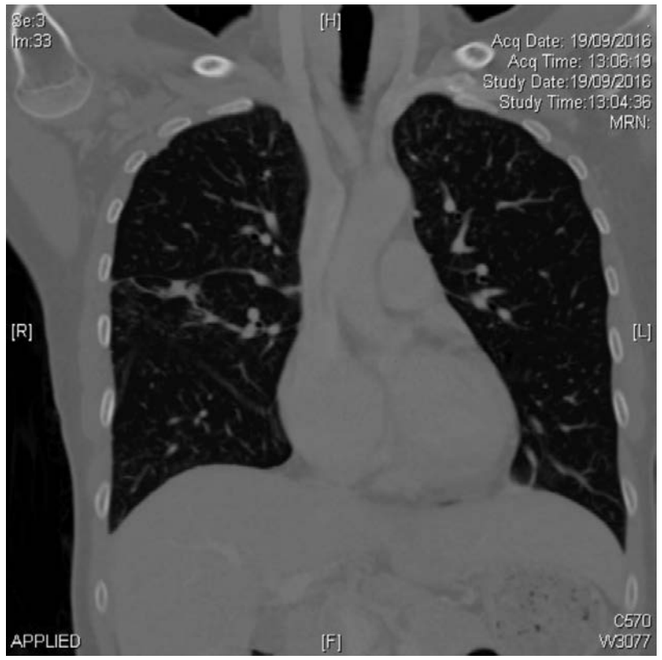

Figure 17. Coronal cuts of the thorax showing the scarring in the right middle zone associated with more distal tree-in-bud.

CASE 10

Masses are found in the pelvis, diagnosed to be malignant ovarian tumour. She was suffering from cancer-associated thromboembolism. Alan Rickman's pancreatic cancer, which eventually caused his demise in January 2016, also presented as a stroke in August 2015. Dr. Martin Samuels recounted the heart-breaking story of Dr Armand Trousseau (1801–1867). In 1865, in lecture 95 of his series, Trousseau described phlegmasia alba dolens (painful white inflammation) and its association with occult cancer. One-and-a-half years later, he himself developed this sign and he correctly diagnosed his own cancer (eventually found to be gastric) which led to his death.[5]

CASE 11

The interpretation is complex so the reader is welcome to submit his or her take on the ECG reading. The rhythm is sinus, but there two abnormalities: the R-R interval is not constant and the p-waves have different morphologies (best seen in the long lead II). Therefore, we feel that there is sinus dysrhythmia plus wandering pacemaker. The poor R-wave progression (in V1 to V4) suggests that the underlying pathology could be ischaemic heart disease.

REFERENCES

1. *Romanelli F, Empey K, Pomeroy C. Macrocytosis as an indicator of medication (zidovudine) adherence in patients with HIV infection. AIDS Patient Care STDS 2002; 16:405-11.*
2. *Geené D, Sudre P, Anwar D, Goehring C, Saaïdia A, Hirschel B. Causes of macrocytosis in HIV-infected patients not treated with zidovudine. Swiss HIV Cohort Study. J Infect 2000; 40:160-3.*
3. *Norell HG. Roentgenologic visualization of the extracapsular fat; its importance in the diagnosis of traumatic injuries to the elbow. Acta Radiol 1954; 42:205-10.*
4. *Jie KE, van Dam LF, Hammacher ER. Isolated fat pad sign in acute elbow injury: is it clinically relevant? Eur J Emerg Med 2016; 23:228-31.*
5. *Samuels MA, King ME, Balis U. Case records of the Massachusetts General Hospital. Weekly clinicopathological exercises. Case 31-2002. A 61-year-old man with headache and multiple infarcts. N Engl J Med 2002; 347:1187-94.*

DR LEONG KHAI PANG
is a senior consultant in the Department of Rheumatology, Allergy and Immunology, Tan Tock Seng Hospital.

DR GERVAIS WAN
is a senior consultant in the Department of Diagnostic Imaging, Tan Tock Seng Hospital

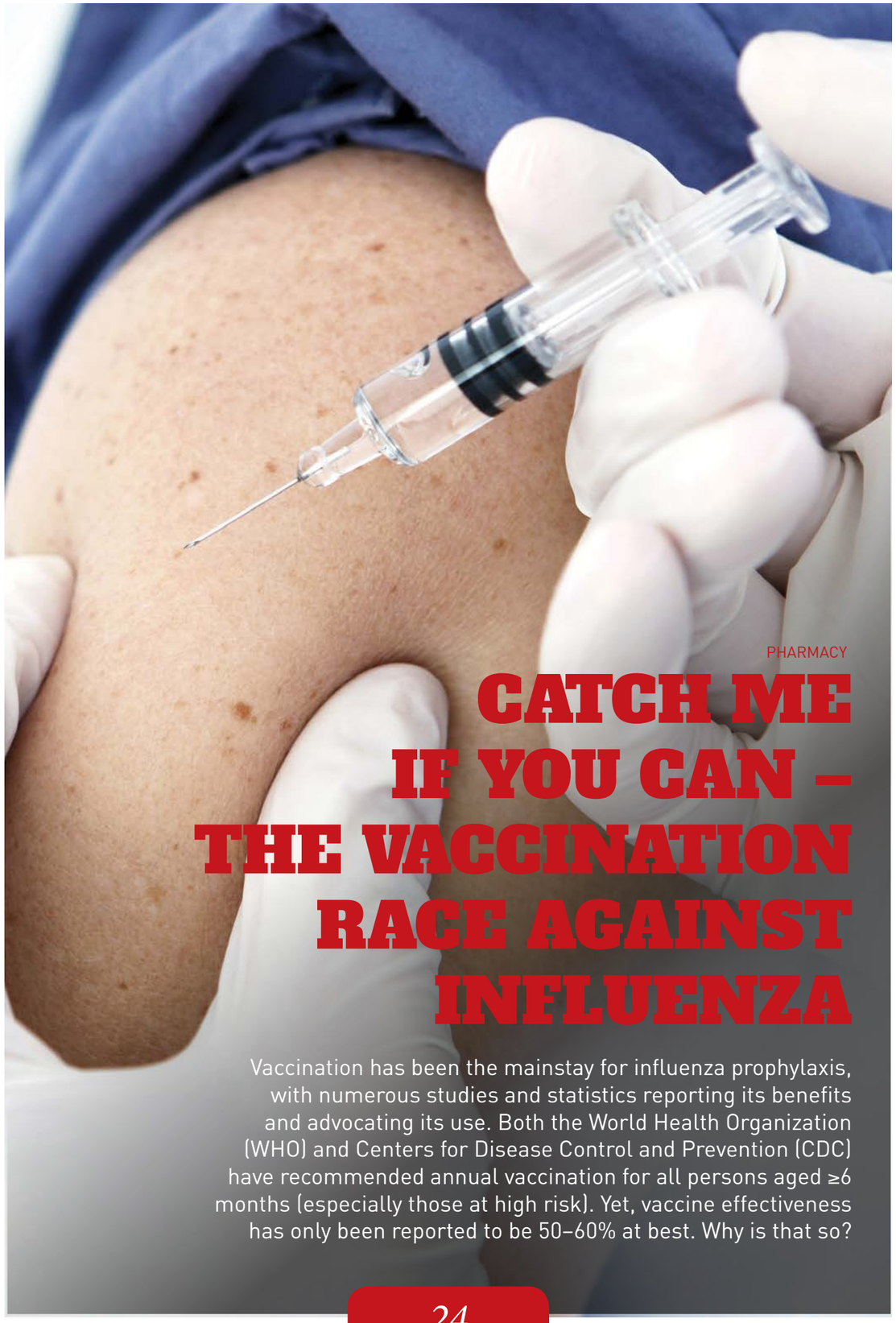

PHARMACY

CATCH ME IF YOU CAN – THE VACCINATION RACE AGAINST INFLUENZA

Vaccination has been the mainstay for influenza prophylaxis, with numerous studies and statistics reporting its benefits and advocating its use. Both the World Health Organization (WHO) and Centers for Disease Control and Prevention (CDC) have recommended annual vaccination for all persons aged ≥6 months (especially those at high risk). Yet, vaccine effectiveness has only been reported to be 50–60% at best. Why is that so?

Influenza virus: Antigenic drift versus shift

There are three antigenic types of influenza viruses: A, B and C. Types A and B are the two main serotypes responsible for causing epidemics or pandemics. Influenza viruses undergo periodic changes in the antigenic characteristics of haemagglutinin and neuraminidase, two major envelope glycoproteins which are critical in virus replication. New virus strains may result from point mutations and recombination events that occur during viral replication, leading to antigenic drifts or shifts.

Antigenic drifts are minor genetic changes that occur continuously as part of natural selection. These accumulate to create new strains that are no longer recognisable to the host immune system, resulting in seasonal outbreaks. Therefore, to keep up with the evolving viruses, WHO reviews the influenza vaccine composition regularly to ensure that the vaccine composition matches the circulating virus strains as much as possible.

Antigenic shifts are abrupt, major changes that result in either new influenza A subtypes or emergence of new virus strains from animal populations. Hence, there is a potential to cause pandemics, as most people have little or no existing immunity against them. Only influenza A viruses undergo antigenic shifts due to their large animal reservoir, which creates more opportunities for genetic reassortment and gives rise to new human subtypes.

Why is there a need for annual vaccination?

The vaccine confers protection when the body develops antibodies against the virus strains approximately 2 weeks after vaccination.

Vaccine effectiveness depends on the host status (e.g. age, health status) as well as the degree of similarity between the circulating viruses and the strains in the vaccines (also known as "vaccine match or mismatch"). As the influenza viruses are constantly evolving, this poses a challenge to the effectiveness of influenza vaccines. Continuous global monitoring and annual reformulation of the vaccine strains are conducted to optimise this vaccine match.

Influenza surveillance is carried out all year round by the WHO Global Influenza Surveillance and Response System, a global public health laboratory network consisting of 141 National Influenza Centres in 111 countries. Twice annually, WHO convenes technical consultations to analyse influenza virus surveillance data and issues recommendations on the composition of the influenza vaccines for the following season (table 1). Recommendations are made in February for the northern hemisphere influenza season, and in September for the southern hemisphere influenza season. Influenza vaccines

2016–2017 Northern hemisphere influenza season	2017 Southern hemisphere influenza season	2017–2018 Northern hemisphere influenza season
A/California/7/2009 (H1N1)pdm09-like virus	A/Michigan/45/2015 (H1N1)pdm09-like virus	
A/Hong Kong/4801/2014 (H3N2)-like virus	A/Hong Kong/4801/2014 (H3N2)-like virus	
B/Brisbane/60/2008-like virus	B/Brisbane/60/2008-like virus	
B/Phuket/3073/2013-like virus[1]	B/Phuket/3073/2013-like virus[1]	

[1] B/Phuket/3073/2013-like virus is included in the quadrivalent vaccines only.

Table 1. WHO recommended composition of influenza virus vaccines for use.

are then manufactured in accordance to WHO recommendations and subjected to approval by national or regional regulatory authorities prior to their release for use.

Using egg-based manufacturing processes, current vaccine production takes an average of 6 months from the selection of virus strains to the final vaccine product. Due to the rapid virus transmission during influenza seasons, vaccine production has to be completed within tight time constraints for use before the peak season starts. Even so, influenza viruses can still evolve during this period and lead to vaccine mismatch.

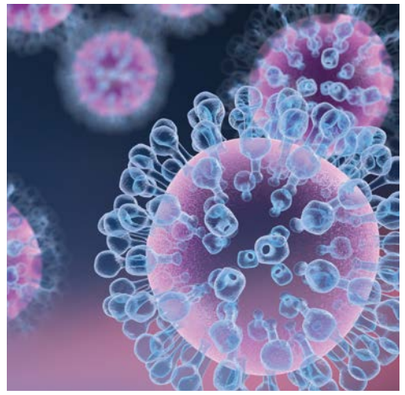

A recent example of vaccine mismatch occurred during the 2014–2015 influenza season in the United States. Fifty-two percent of the circulating influenza virus strains were antigenically different (drifted) from A/Texas/50/2012, the H3N2 virus strain in the 2014–2015 northern hemisphere vaccine. Drifted H3N2 viruses were first detected in late March 2014, a month after WHO released their recommendations for the 2014–2015 northern hemisphere vaccine. These drifted viruses were mainly A/Switzerland/9715293/2013 viruses, which is the H3N2 virus strain selected for the following 2015 southern hemisphere influenza vaccines. As influenza A(H3N2) viruses predominated during this season, this led to an overall vaccine effectiveness estimate of only 19%.

Singapore in a unique situation

Singapore is situated in the tropics and experiences influenza all-year round, with a bimodal increase in incidence generally observed in the period of April to July and the period of November to January. Influenza A(H3) virus has been the predominant circulating virus strain during the past 12 months (figure 1). Like other countries in the tropical regions, the optimal formulation and timing of influenza vaccinations in Singapore are unknown.

At present, WHO recommendations for vaccine composition depend mainly on whether the target populations are in the temperate regions of the northern or southern hemisphere. Although the WHO recommends that the choice of formulation to be used for countries in equatorial regions should be guided by epidemiological considerations, there is often too little information available to make a rational choice.

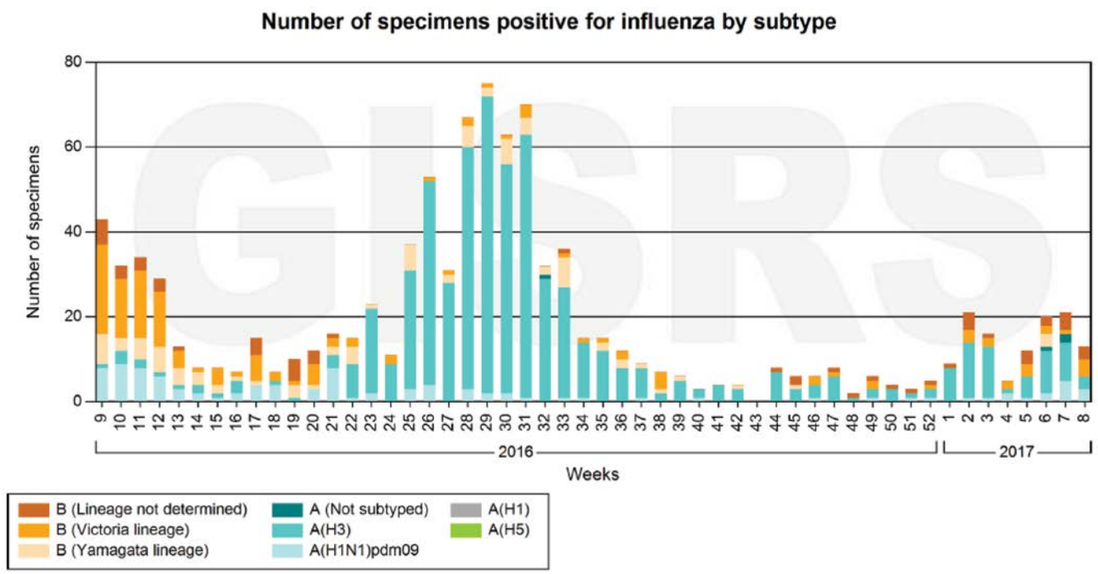

Figure 1. Influenza activity during the period of March 2016 to February 2017 in Singapore (FluNet database by Global Influenza Surveillance and Response System, 2 March 2017).

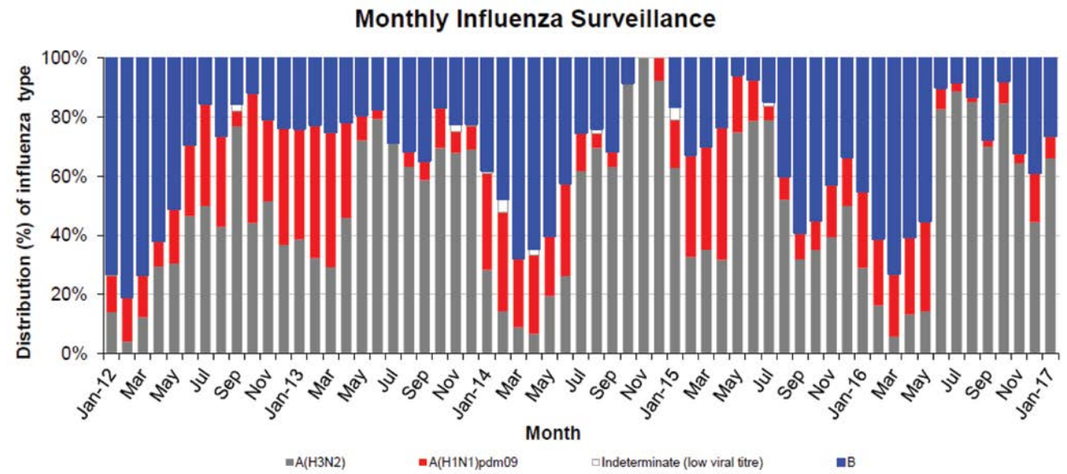

Figure 2. Distribution of influenza subtype during the period of January 2012 to January 2017 in Singapore (Ministry of Health Weekly Infectious Diseases Bulletin Vol. 14 No. 8 2017, 2 March 2017).

In temperate regions, there are clear seasonal variations in influenza activity, with a distinct peak during the winter months of November–March and April–September in the northern and southern hemispheres, respectively. In countries with tropical or subtropical climates, influenza seasonality is more variable, as shown by an analysis of influenza surveillance data collected between 2006 and 2011 in 10 countries in South Asia and Southeast Asia. Year-round circulation was noted in countries that lie on or close to the Equator (e.g. Indonesia, Malaysia and Singapore), whereas influenza activity showed a distinct peak between during the summer monsoon season in July to October in countries located at higher latitudes (e.g. Cambodia and the Philippines). Such undefined patterns of influenza activity complicate vaccination policies in tropical regions.

What to expect next?

The year 2016 saw the entry of two quadrivalent inactivated vaccines into our local market: FluQuadri (Sanofi Aventis) and Fluarix Tetra (GlaxoSmithKline). Both vaccines are considered interchangeable, but differ in their licensed age ranges (≥6 months for FluQuadri; ≥3 years for Fluarix Tetra).

Since the mid-1980s, two genetic lineages of influenza B viruses have circulated. The potential benefit of using a quadrivalent vaccine was illustrated by a report during 12 seasonal influenza outbreaks between 1999 and 2012: 41.7% of all influenza B infections were caused by viruses of the genetic lineage that was not included in the trivalent vaccine used during those seasons.

As seen by the local surveillance data (figure 2),

> Singapore is situated in the tropics and experiences influenza all-year round, with a bimodal increase in incidence generally observed in the period of April to July and the period of November to January.

mismatch commonly occurs between recommended and circulating B-strain and it is difficult to make accurate predictions of the dominant circulating B strain. Inclusion of both lineages in vaccines may confer better protection against influenza. Considering that the immunogenicity and safety of the quadrivalent vaccines are similar to that of the trivalent vaccines, TTSH has decided to switch over to quadrivalent vaccines from the 2017 influenza season onwards.

The bottom line

Annual influenza vaccination is an important public health measure for prevention of influenza. To catch up with the ever-evolving viruses, global surveillance efforts play a key role in the production cycle of influenza vaccines by predicting the vaccine composition in advance. However, the current vaccination strategy is still vulnerable to the emergence of epidemic or pandemic strains that are not represented in the vaccine.

In the event of a vaccine mismatch, influenza vaccination is still recommended. Depending on the degree of antigenic drift from vaccine viruses and the proportion of circulating drifted viruses, vaccination may still offer protection against circulating influenza strains that have not undergone antigenic drift, as well as cross-protection to reduce the risk of severe complications such as hospitalisation and death.

FURTHER READING

1. *World Health Organization. Influenza. Retrieved from http://www.who.int/topics/influenza/en/*
2. *Centers for Disease Control and Prevention (2014). Prevention and control of seasonal influenza with vaccines: Recommendations of the Advisory Committee on Immunization Practices – United States, 2014-15 Influenza Season. Retrieved from http://www.cdc.gov/flu/professionals/acip/*
3. *Hibberd PL. Seasonal influenza vaccination in adults. In: UpToDate, Post, TW (Ed), UpToDate, Waltham, MA, 2015. (Accessed on February 25, 2017)*
4. *Saha S, Chadha M, Al Mamun A. Influenza seasonality and vaccination timing in tropical and subtropical areas of southern and south-eastern Asia. Bulletin of the World Health Organization 2014; 92:318-330*
5. *Heikkinen T, Ikonen N, Ziegler T. Impact of influenza B lineage-level mismatch between trivalent seasonal influenza vaccines and circulating viruses, 1999-2012. Clin Infect Dis 2014; 59(11):1519-24.*
6. *Ministry of Health, Singapore. Weekly Infect Dis Bull 2017; 14(8):1-8.*

MS SHIRLENE HO
is a pharmacist in the Department of Pharmacy, Tan Tock Seng Hospital.

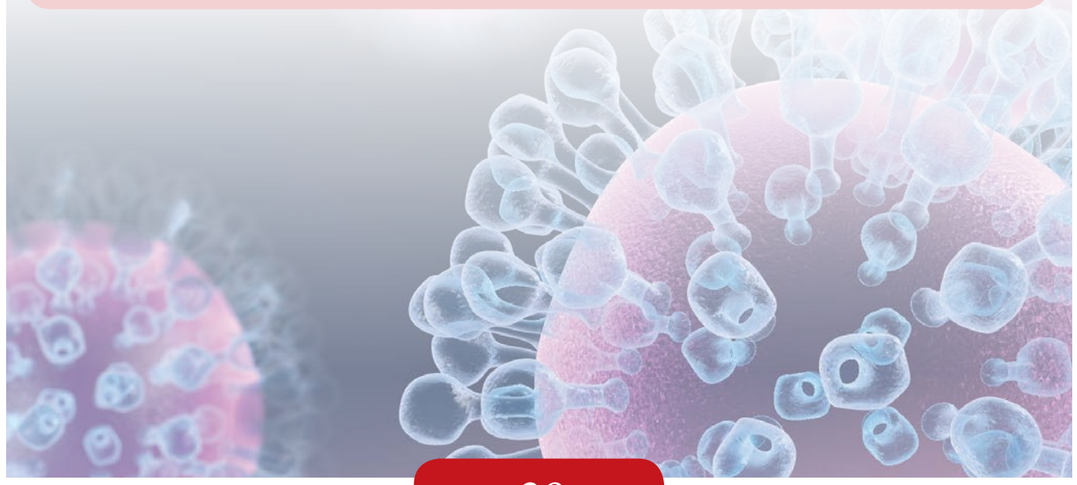

RADIOLOGY QUIZ

Every issue, we present radiology and ECG quizzes of interesting cases seen in TTSH. Put your knowledge to the test with this issue's scenarios.

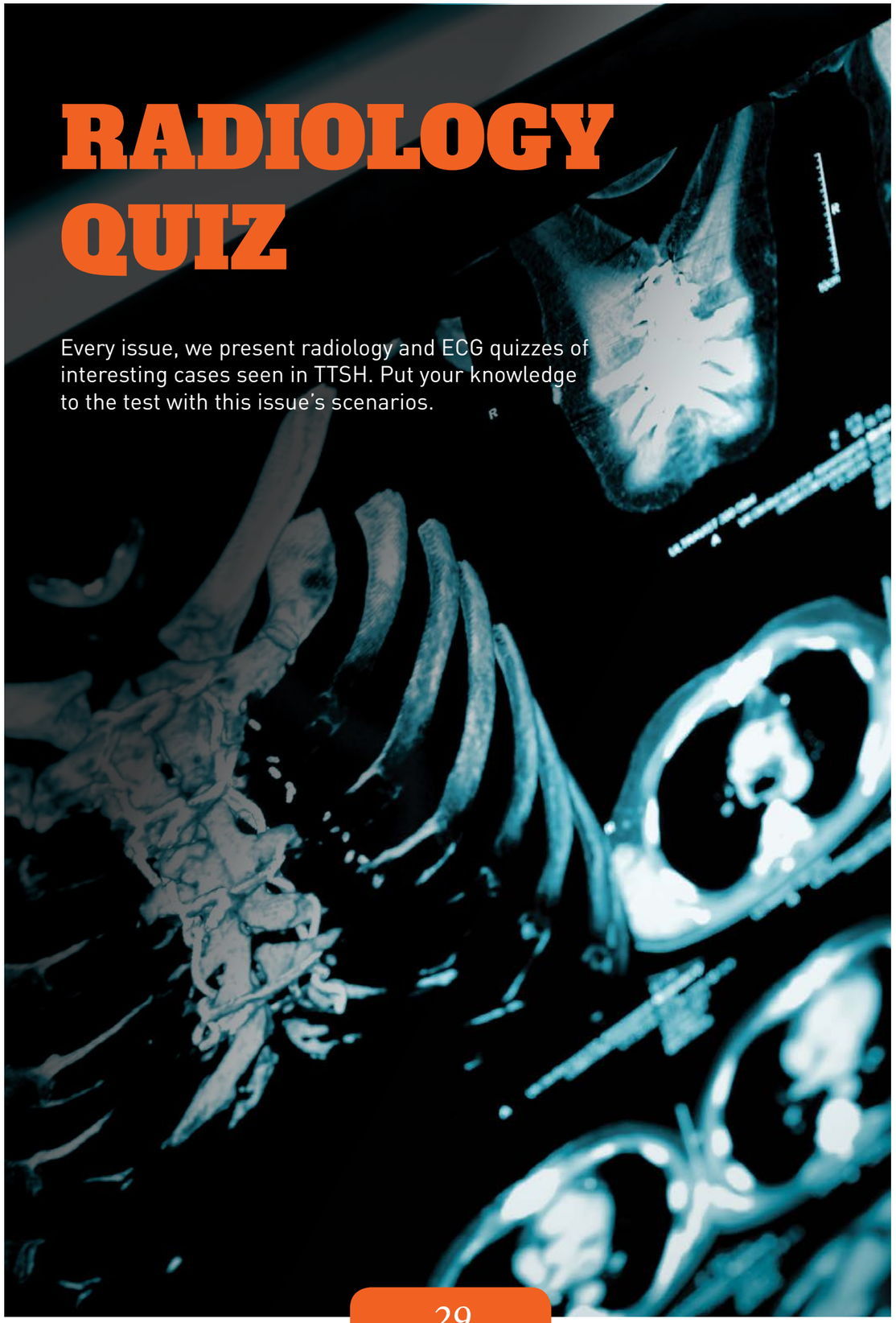

A 70-year-old Chinese lady presented with a 2-day history of right hypochondrium (RHC) pain after dinner. She vomited several times afterwards and claims that she has had previous similar episodes when she was younger. There were no constitutional symptoms. On examination, RHC tenderness was found together with a positive Murphy's sign as well as voluntary abdominal guarding. Vital signs were stable. She was afebrile and laboratory tests revealed a very mildly elevated white cell count. Plain abdominal radiograph was unremarkable and the Emergency Room Physician ordered a CT scan of the abdomen and pelvis.

QUESTION 1

What do the selected contrast axial and coronal CT images show (figure 1)?

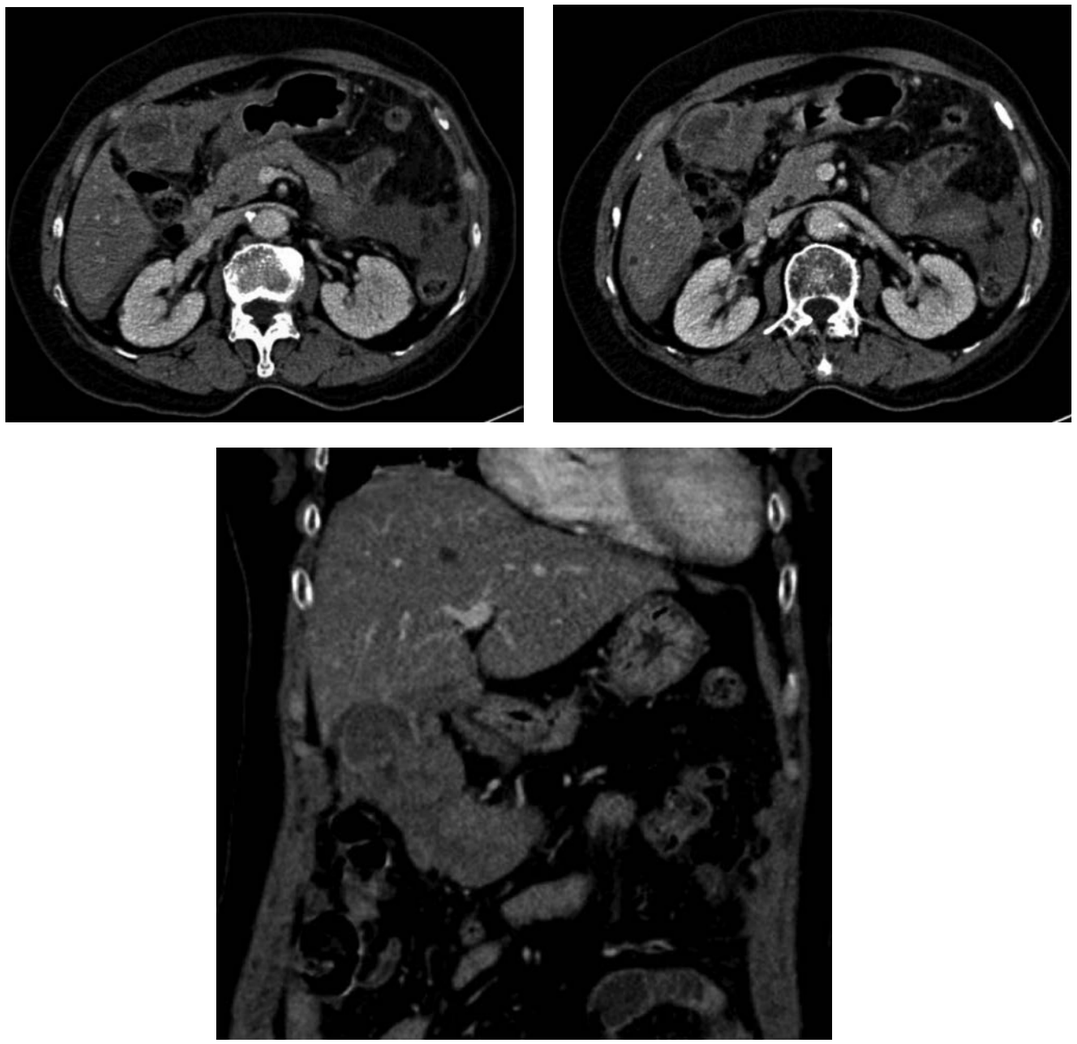

Figure 1. CT scan images of abdomen and pelvis.

QUESTION 2

The presumptive diagnosis of acute perforated haemorrhagic cholecystitis was made. From the surgeon's point of view, the hyperdense structure adjacent to the gallbladder was of concern and the differential diagnoses of a blood clot or soft tissue mass have significant surgical implications. A contrast MRI was performed to distinguish them. From the MRI images (figure 2), which one of the differentials do you think is more likely?

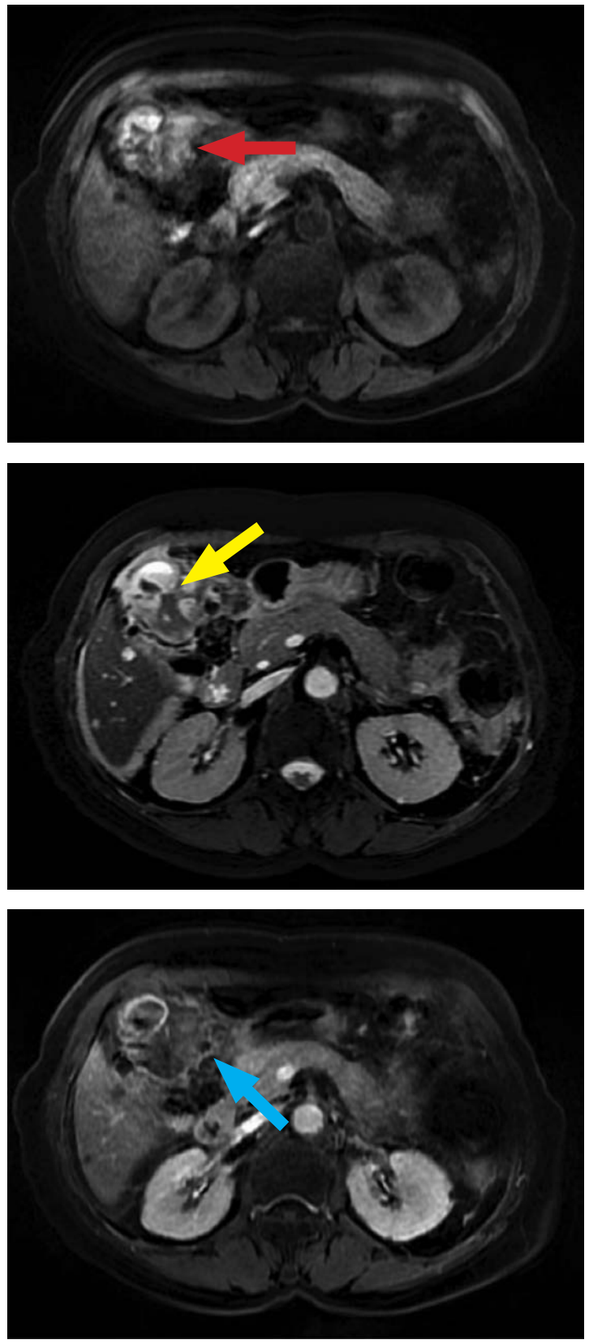

Figure 2. MRI images of abdomen pre- (T1W and T2W F5, top) and post-contrast (T1W F5, bottom).

ANSWER 1

The gallbladder wall is thickened with surrounding inflammatory changes. There is also a segment of mural discontinuity over the medial aspect of the gallbladder wall (red arrows, figure 3) with an adjacent irregular, hyperdense structure present which is inseparable from the wall (yellow arrows, figure 4). A small amount of hyperdense ascites is also present (blue arrows, figure 5).

The findings are compatible with acute cholecystitis complicated by perforation and the small amount of hyperdense ascites is suggestive of haemoperitoneum. The nature of the adjacent, contiguous hyperdense structure is difficult to establish but could be a blood clot or a soft tissue mass.

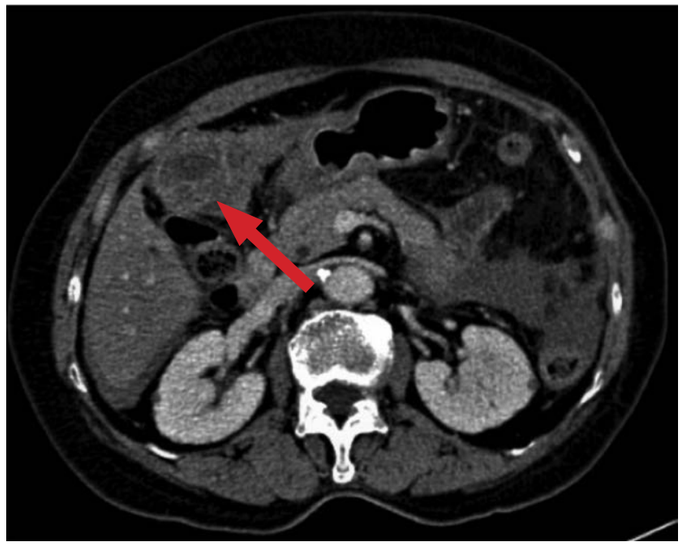

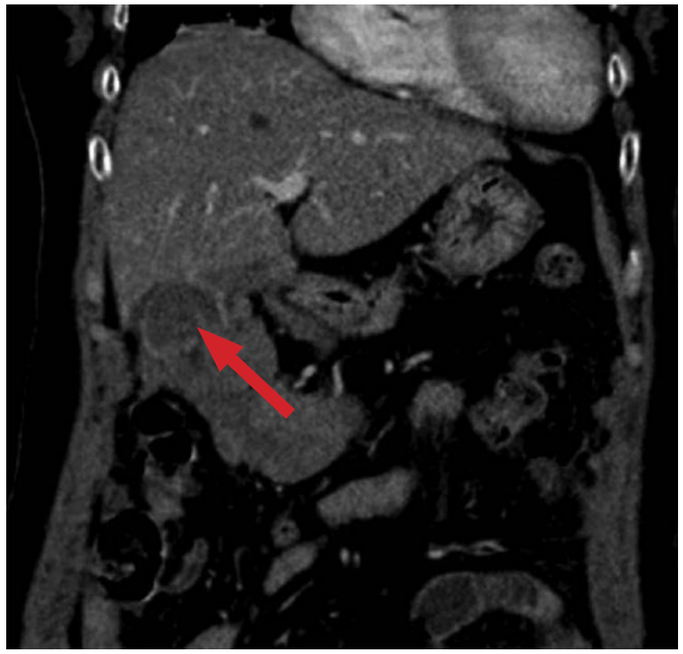

Figure 3. CT scans of abdomen and pelvis showing mural discontinuity over the medial aspect of the gallbladder wall (red arrows).

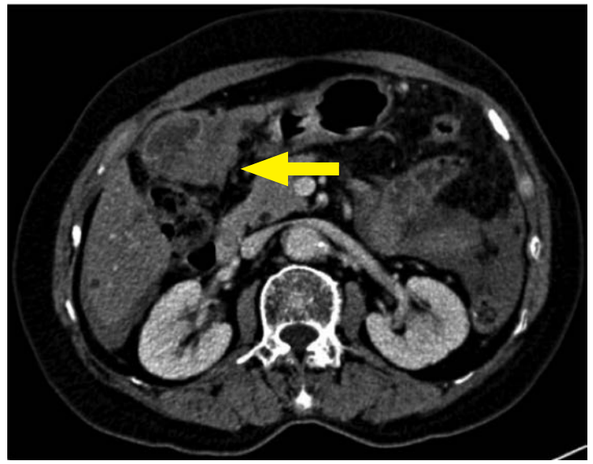

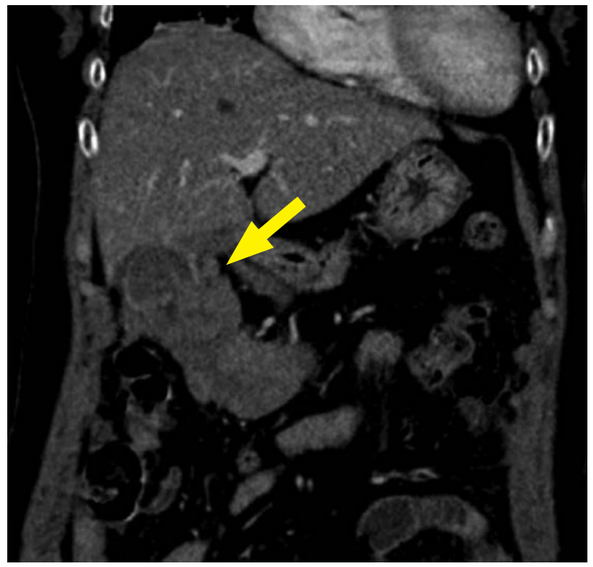

Figure 4. CT scans of abdomen and pelvis showing hyperdense structure present which is inseparable from the wall (yellow arrows).

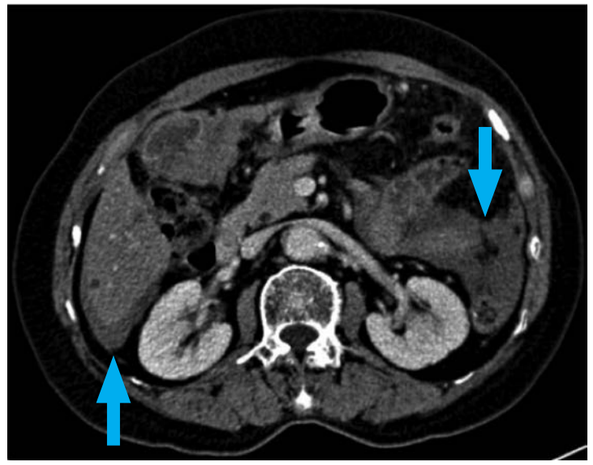

Figure 5. CT scan of abdomen showing presence of a small amount of hyperdense ascites (blue arrows).

ANSWER 2

The structure is bright on the T1W pre contrast sequence (figure 2, red arrow) and predominately dark on the T2W sequence (yellow arrow) with no solid internal enhancement seen on the post contrast sequence (blue arrow). These signal characteristics on MRI, combined with the CT appearances and clinical setting would make this structure compatible with a haematoma. Based on this information, the surgeon decided to operate and confirmed the findings of haemorrhagic, perforated cholecystitis with blood clots in all four quadrants. The gallbladder was partially wrapped around with blood clot and omentum. The patient eventually made an uneventful recovery and discharged well.

Discussion

Haemorrhage is a rare but potentially fatal complication of acute cholecystitis. The mechanism is thought to be due to a transmural inflammatory process that causes erosion of the mucosa and ischemia, leading to mucosal breakdown, erosion into gallbladder vessels, and haemorrhage into the gallbladder lumen or the abdominal cavity. The condition may be exacerbated if the patient is receiving anti-coagulation or anti-platelet medication (e.g. aspirin).

The patient with haemorrhage into the gallbladder may present in a variety of ways. The blood may clot inside the gallbladder, resulting in gallbladder distension and possibly perforation into the abdomen with resultant peritonitis such as the case of our patient. If there is no gallbladder wall perforation, the blood may also clot inside the common bile duct, resulting in obstructive symptoms. Finally, the blood may enter into the bowel lumen, with resultant haematemesis or melaena.

The definitive treatment of haemorrhagic cholecystitis is cholecystectomy, or, in patients who are unfit for surgery, cholecystostomy. As our patient was relatively fit with a lack of any underlying significant co-morbidities, surgery was performed successfully.

FURTHER READING

1. *Morris DS, Porterfield JR, Sawyer MD. Haemorrhagic cholecystitis in an elderly patient taking aspirin and cilostazol. Case Rep Gastroenterol 2008; 2(2):203-7.*
2. *Gremmels JM, Kruskal JB, Parangi S, Kane RA. Haemorrhagic cholecystitis simulating gallbladder carcinoma. J Ultrasound Med 2004; 23:993-5.*
3. *Avakoff JC, Wolfman EF Jr. Hemocholecyst: report of two cases, one associated with steroid administration. Surgery 1969; 66:830-4.*
4. *Hudson PB, Johnson PP. Hemorrhage from the gallbladder. N Engl J Med 1946; 234:438-41.*

DR JUSTINE KWAN
is an associate consultant in the Department of Diagnostic Radiology, Tan Tock Seng Hospital.

ECG QUIZ

A 60-year-old gentleman with past history of hypertension and cigarette smoking presented to the Emergency Department for chest discomfort. The chest pain started one week prior to presentation and had improved by the time he came to the hospital.

At the Emergency Department, the patient was comfortable and pain-free. His blood pressure was 105/50 mmHg and he had normal oxygen saturation on room air. Physical examination was unremarkable with no signs of heart failure.

His resting 12-lead electrocardiogram (ECG) is shown (figure 1):

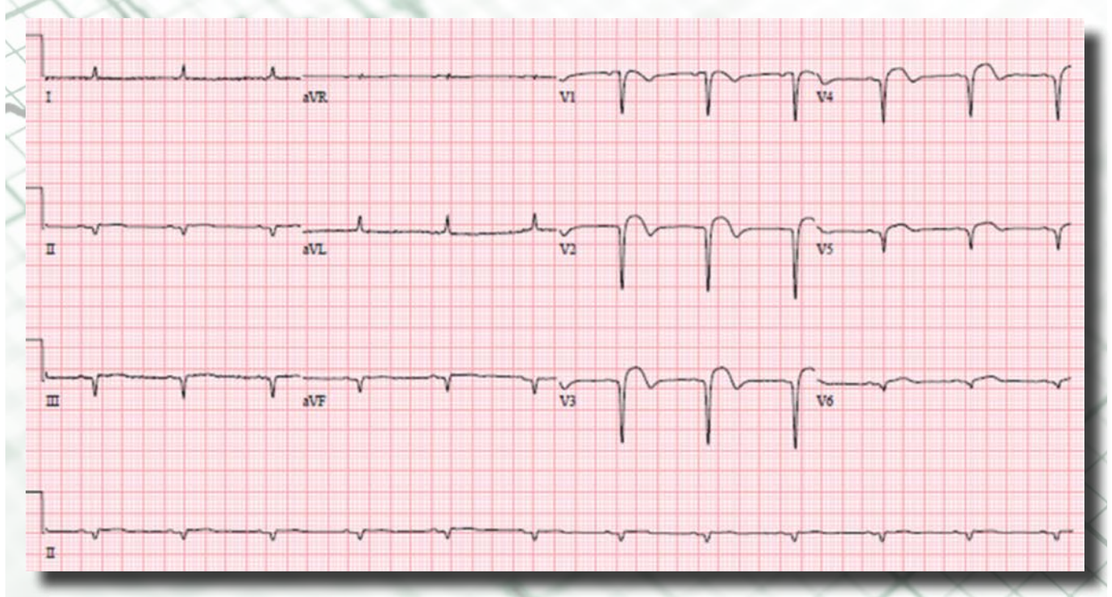

Figure 1. Resting 12-lead ECG performed at the Emergency Department.

QUESTIONS

1. What is the ECG diagnosis?
2. What investigation would you perform to confirm the diagnosis?

ANSWER

1. There are pathological 'Q' waves with associated ST segment elevation over the anterior leads, consistent with evolved anterior myocardial infarction with possible ventricular aneurysm. In addition, there are also 'Q' waves over the inferior leads suggestive of an old inferior myocardial infarction.

2. Transthoracic echocardiogram.

Discussion

A left ventricular (LV) aneurysm is a localised bulge of scarred and weakened myocardium from a healed transmural myocardial infarction. This is not to be confused with a 'pseudoaneurysm' which is a contained rupture of the myocardium or blood vessel.[1]

The presence of an LV aneurysm should be suspected if the ECG shows persistent ST segment elevation after the acute phase of myocardial infarction. In this case, the diagnosis was confirmed on a transthoracic echocardiogram (figure 2).

With the availability of early percutaneous coronary intervention, LV aneurysms are now less commonly seen after myocardial infarction.[2] When present, however, LV aneurysms are associated with poorer prognosis due to associated complications such as ventricular arrhythmias, thrombi formation and aneurysm rupture.

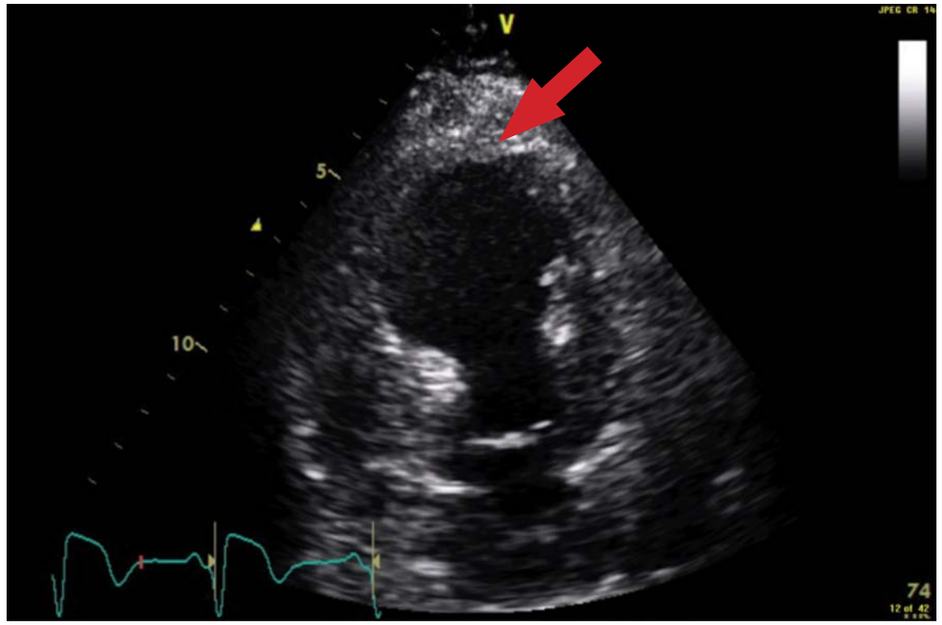

Figure 2. Resting transthoracic echocardiogram demonstrating an aneurysmal left ventricular apex and part of the septum.

REFERENCES

1. *Hulten EA, Blankstein R. Pseudoaneurysms of the heart. Circulation. 2012;125(15):1920-5.*
2. *Lucas LA, Somerville C. Images in clinical medicine. Left ventricular aneurysm. N Engl J Med. 2014;370(3):e5.*

DR YEW MIN SEN
is an associate consultant in the Department of Cardiology, Tan Tock Seng Hospital.