Tan Tock Seng Hospital

Beyond Exudate Absorption: Using Hydrofiber Foam Dressing For Wound Management - 1 Case Study

Karine Goh Cheng Cheng, Senior Staff Nurse, Department of Nursing and Wound Care, Tan Tock Seng Hospital, Singapore

Day 1
112cm2

Day 5
90cm2

Day 37
44cm2

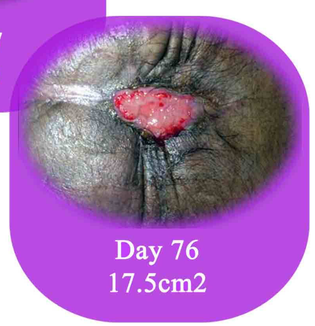

Day 76
17.5cm2

Background:

- Open abdomen often poses a formidable management challenge for the general, trauma or plastic and reconstructive surgeon.[5]
- Open abdomen had wound with exposed bowel, poses addtional difficulty in wound management for clinicians.
- Healing by secondary intention will eventually provide the necessary coverage although it is lengthy and requires frequent dressing changes.
- A moist environment would provide an optimum conditions for wound healing.[3]
- The advantages include promotion of
  - rapid epithelization of acute wounds
  - enhanced healing of chronic wounds
  - reduced pain
  - reduced chance of infection.[1]
- Skin barrier function has been shown to be compromised in peri-wound skin compared with normal skin.[3]
- Exposure to wound exudates puts peri-wound skin at risk of further damage.[3]
- Hydrofiber® Gelling Foam dressing rapidly absorbs and retains exudate and bacteria directly into its fibres.
- This helps to reduce risk of maceration.[2]
- Hydrocolloid- based contact layer gently adheres to periwound skin, whilst gelling over the wound to minimise pain during weartime and on dressing removal
- The waterproof foam-film outer layer gently protects and cushions, moves excess fluid via moisture evaporation to provide an optimal environment.
- Versiva XC™ is the only dressing that combines three proven technologies: Hydrocolloid Layer, Hydrofiber® Technology Layer and Foam--film*.

Aims:

- To evaluate the effectiveness of Versiva XC, a Hydrofiber® Gelling Foam Dressing on a patient who required excessive wound exudates management and peri-wound skin protection.

Methods:

- Case Study on a patient with abdominal wound dehiscence with small bowel exposure was chosen
- Decision was made by the physician to leave the wound to heal by secondary intention.
- Hydrofiber Gelling Foam Dressing was applied and change in every 5days.
- Sign of wound exudate leakage, peri-wound maceration, characteristic of wound bed and easy application and removal of dressing were monitored.
- Photographs were taken before application, on the first change of dressing,37th and 76th day after application.

Results:

- During the first dressing change, Hydrofiber Gelling Foam Dressing was observed to be intact with no excessive wound exudates leakage.
- Dressing was easily removed without traumatizing wound bed and its surrounding skin. Abdominal wound was clean and granulating tissue was visible. Size of small bowel exposure was noted to be decreasing with no sign of peri-wound maceration.
- Patient was monitored at outpatient 37 days after the initiation of Hydrofiber Gelling Foam Dressing. Wound bed remained clean and healthy with no peri-wound maceration noted.
- Area of small bowel exposure was no longer visible. Total wound size had also decreased by 84.4%.

Conclusion:

- Hydrofiber Foam Dressing effectively protects peri-wound skin from maceration against highly exudative wound.
- Supports wound healing through a moist environment
- Provide efficient cushioning to the fragile wound bed.

Acknowledgement :

1. ConvaTec,
A Bristol-Myers Squibb Company

2. Diane Eng Li Kheng
Nurse Clinician
Tan Tock Seng Hospital, Singapore

References:

1.Armstrong DG. et al Guidelines regarding Negative Pressure Wound Therapy in Diabetic foot. 2004.

2.Bishop S et al (2003) Importance of moisture balance at the wound dressing interface. Journal of Wound Care. 12, 4, 125-128.

3.Cameron J (2004) Exudate and care of the peri-wound skin. Nursing Standard. 19,7, 62-68.

4.Robinson BJ (2000) The use of a hydrofibre dressing in wound management. Journal of Wound Care. 9, 32-34

5.Swan M, Banwell PE. Topical Negative Pressure: Advanced management of the open abdomen. Oxford Wound Healing Society. 2003.

6.www.Versiva.com