

## Peritoneo-Cutaneous Fistula Secondary to Skin Excoriation from a Large Chronic Incisional Hernia

### Dear Editor,

Incisional hernias are common complications following abdominal surgery with an incidence of 2% to 20% after midline laparotomy.<sup>1</sup> Umbilical fluid discharge is, however, an unusual presenting complaint and may arise from structural abnormalities persisting from birth such as a patent urachus or secondary to instrumentation. Here we report a case of a peritoneo-cutaneous fistula arising from a large incisional hernia. It is to our knowledge that this may be the first case reported in literature.

### Case Report

An 83-year-old female was referred for evaluation of fluid discharge from her umbilicus for 5 years. The discharge was straw-coloured, clear, intermittent and prominent upon coughing or straining, resulting in occasional staining of clothing. There was no abdominal pain, fever, dysuria or loss of weight, or progression of discharge over time.

She underwent a partial gastrectomy for gastric carcinoma 2 decades ago without chemotherapy or radiotherapy; no

recurrence was reported. On examination, a large irreducible incisional hernia over the mid-line scar with an 8-cm fascial defect, and a 1-mm sinus at the base of the distorted umbilicus with some straw-coloured discharge were seen. No introital mass was present to suggest pelvic organ prolapse.

Given her age and history of carcinoma, our initial differentials included a patent urachus and cutaneous seeding of metastases. As there was no palpable mass or nodule and the sinus edges looked benign, the first became our working diagnosis. Urinary analysis yielded pyuria (>255 leucocytes/ $\mu\text{L}$ ) and the accompanying culture grew *Enterobacter Aerogenes*. Appropriate antibiotics were initiated. Serum creatinine was 99  $\mu\text{mol/L}$  (range, 40 to 85) and fluid creatinine 83  $\mu\text{mol/L}$ .

Recognising the inappropriately low fluid creatinine level, a sinogram was performed. This revealed a peritoneo-cutaneous fistula with free flow of contrast into the hernia sac (Figs. 1 and 2). We counselled her on the finding and possibility of peritonitis. Unfortunately, she refused an incisional hernia repair and closure of fistula tract. To our

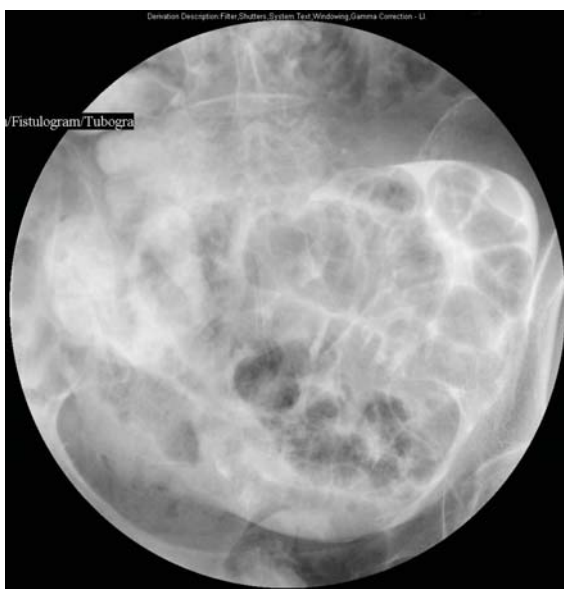

Fig. 1. Anterior-posterior view of sinogram revealing free contrast in the peritoneal cavity lining the visceral surface of the small bowel loops.

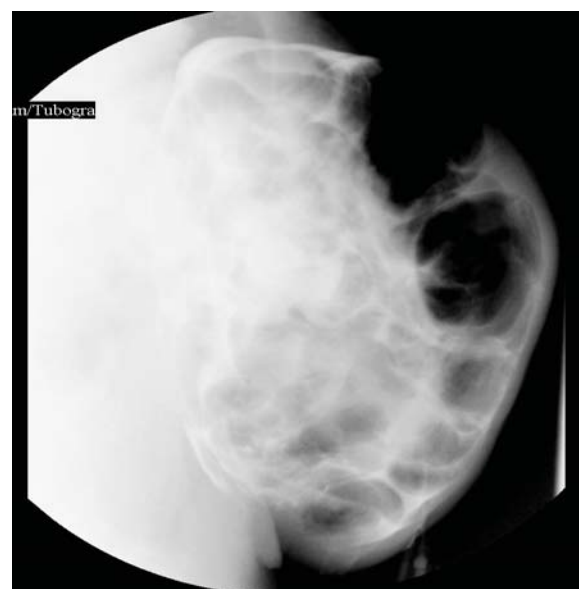


Fig. 2. Lateral view of sonogram.

surprise, when she consented to a repair of the skin defect, we found that the fistula had spontaneously sealed off with a scab. She has subsequently defaulted follow-up.

### Discussion

Incisional hernias can have a varied presentation. While skin excoriations are not uncommon, peritoneo-cutaneous fistulas secondary to a neglected chronic incisional hernia have not been reported. Other reports were related to foreign bodies: un-retrieved gallstones<sup>2</sup> or intra-uterine Dalkon shield.<sup>3</sup> Bacterial peritonitis can ensue from retrograde infection, hence surgical correction is recommended. In the same light, sinography too can cause peritonitis, hence its role debatable. Fluid from a patent urachus would demonstrate urine creatinine levels. Urine creatinine in adults aged 18 to 93 years range from 6.23 to 15.33 mmol/L.<sup>4</sup> Our finding (83 µmol/L) meant it was unlikely to be urine, unless it was grossly diluted. A patent urachus seldom manifests until maturity or old age, as bladder contractions commence from the apex passing towards the base. As it opens into the bladder apex, temporary closure occurs during micturition. Therefore it presents after bladder distension from obstruction such as benign prostatic hyperplasia or pelvic prolapse. Further evaluation of a patent urachus may include a voiding cysturethrogram or sonogram.<sup>5,6</sup>

### REFERENCES

1. Nieuwenhuizen J, Halm JA, Jeekel J, Lange JF. Natural course of incisional hernia and indications for repair. *Scand J Surg* 2007;96:293-6.
2. Steerman PH. Delayed peritoneal-cutaneous sinus from unretrieved gallstones. *Surg Laparosc Endosc* 1994;4:452-3.
3. Slaughter L, Morris DJ. Peritoneal-cutaneous fistula secondary to a perforated Dalkon shield. *Am J Obstet Gynecol* 1976;124:206-7.
4. Simeckova A, Zamrazil V, Cerovska J. The effect of age on levels of magnesium and creatinine in the urine. *Cas Lek Cesk* 1998;137:753-6.
5. Cilento BG, Jr, Bauer SB, Retik AB, Peters CA, Atala A. Urachal anomalies: defining the best diagnostic modality. *Urology* 1998;52:120-2.
6. Yiee JH, Garcia N, Baker LA, Barber R, Snodgrass WT, Wilcox DT. A diagnostic algorithm for urachal anomalies. *J Pediatr Urol* 2007;3:500-4.

Ek Khoon Tan,<sup>1</sup>MBBS, MRCSEd, Vishalkumar G Shelat,<sup>1</sup>MRCSEd, MRCPS(Glasg), MMed(Surg), Li Tserng Teo,<sup>1</sup>MBBS, MRCSEd, MMed(Surg), Ming Terk Chiu,<sup>1</sup>MBBS, FRCS, FAMS

<sup>1</sup>Department of General Surgery, Tan Tock Seng Hospital

Address for correspondence: Dr Tan Ek Khoon, Department of General Surgery, Tan Tock Seng Hospital, 11 Jalan Tan Tock Seng, Singapore 308433. Email: ekkhoon.tan@mohh.com.sg